

Trienophorus

I. Causative Agent and Disease

Trienophorus crassus is a cestode (tapeworm) belonging to the family Trienophoridae that parasitizes fish as plerocercoid larvae (1 mm X 30 cm) found encysted in the musculature. These cestodes can also be found as adults living in the guts of predatory fish.

II. Host Species

There are many fish intermediate hosts for the plerocercoid (larval) stage of *Trienophorus* in North America and Europe. The definitive hosts are piscivorous fishes such as northern pike.

III. Clinical Signs

Trienophorus often stimulates formation of yellow to white cysts of host connective tissue that surround the plerocercoids in the muscle. Encysted or unencysted larvae can cause localized muscle discoloration and necrosis. Liver dysfunction and blood loss can occur from larval migration through the viscera and may be associated with hemorrhaging, necrosis, fibrosis, edema and tissue discoloration. Severe adult tapeworm infestations in the gut can cause perforations, mechanical blockage with distension and prevent nutrient uptake causing emaciation and anemia.

IV. Transmission

The life cycle of this tapeworm occurs in freshwater where eggs are shed from adult worms living in the intestinal tracts of the final hosts (usually predatory fish). The cestode eggs, containing a coracidium, are eaten by copepods and develop into proceroids. The copepods are eaten by the second intermediate fish host where the proceroids migrate from the intestinal tract to the muscle

and develop into the plerocercoid stage. The life cycle of the worm is completed when the parasitized fish is eaten by the final fish host, commonly a northern pike. Eggs are produced after the worm develops into an adult in the intestinal tract of the final fish host.

V. Diagnosis

Diagnosis is made by observation of encysted or unencysted white plerocercoids in the skeletal musculature of a parasitized fish. Identifying microscopic features of the plerocercoid scolex (head) include dorsal and ventral pairs of trident shaped hooks on an apical disc. Adult worms are larger and found in the intestinal tract.

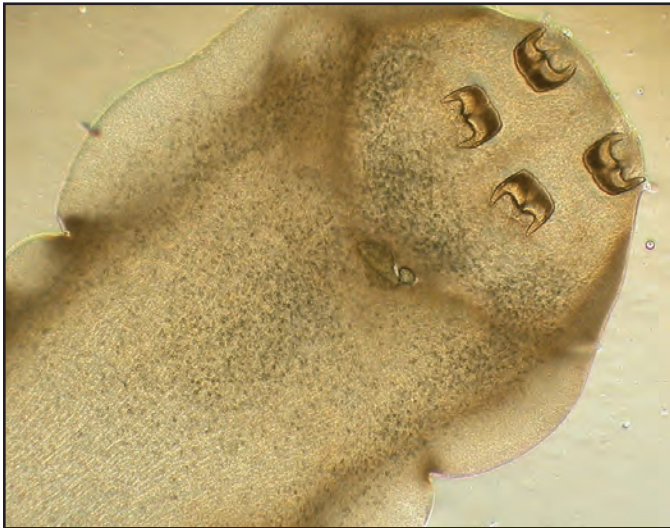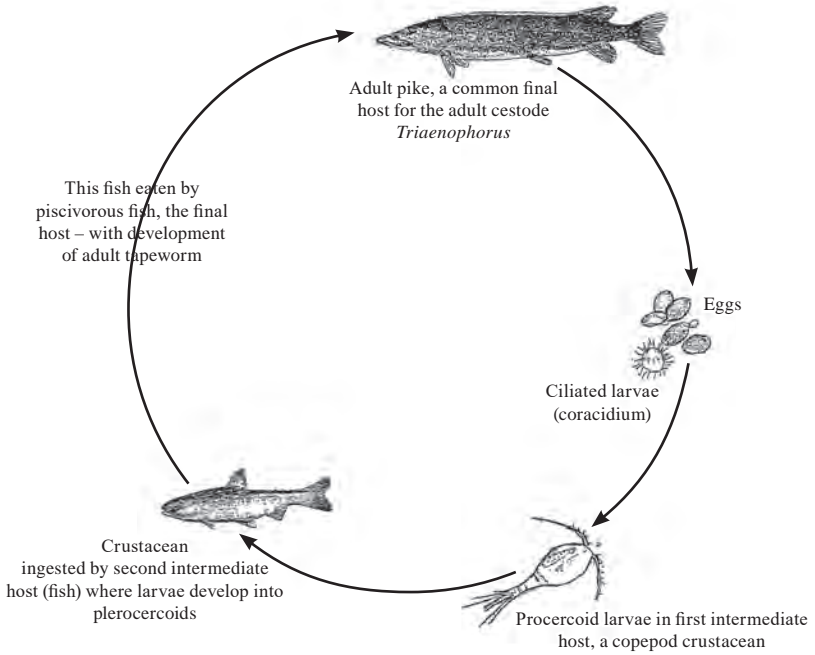
VI. Prognosis for Host

Prognosis for the fish host depends on the degree of cestode infestation, the age and size of the fish and exposure to other stressors. Generally, these parasites have caused health problems with juvenile cultured fish but are well tolerated when occurring as natural infestations of larger healthy fish.

VII. Human Health Significance

Although this tapeworm is not known to occur in man or other warm-blooded animals, infested fish flesh is unsightly.

Trienophorus Life Cycle



Characteristic trident shaped hooks on scolex of *Trienophorus crassus* plerocercoid found in fish muscle, X 40.