

Salmincola

I. Causative Agent and Disease

Parasitic copepods of the genus *Salmincola* are most often found attached to gill filaments, opercula, tissues within the mouth cavity, and fins of salmonid fishes. The parasites feed on blood and epithelial tissues of their hosts. *Salmincola* species are restricted largely to freshwater but may survive on salmonids while at sea. The adult female copepods are larger than the males and attach permanently to the fish host with a modified mouth part known as a bulla that is inserted into the host tissues. Host damage by parasitic copepods depends on the location of the attachment site, the species of parasite, and the size and type of bulla. Gill attachment by *Salmincola* can damage delicate epidermal tissues resulting in necrosis and loss of surface area for respiration. Attachment may also provide portals of entry for secondary invaders such as bacteria and fungi.

II. Host Species

Salmincola has been reported more commonly from salmonid species in North America and Europe.

III. Clinical Signs

Salmincola copepods are visible to the naked eye when attached to fins, bases of fins, skin, opercula, gills and branchial chamber. Gill damage caused by displacement from *Salmincola* can be extensive resulting in retarded filament growth and tissue necrosis. Gill hyperplasia and hypertrophy may also lead to fusion of the filaments, thus reducing surface area for necessary gas exchange and respiration.

IV. Transmission

Salmincola have a direct, but complicated life cycle. Females produce two

clusters of eggs twice during a 3-month life span. Eggs hatch into a larval form that can survive free-swimming for several days. The larvae attach to gills or fins of a fish host and molt into 4 successive larval stages and degenerate into grub-like parasites. Males then detach and copulate with the females, after which the males die. Females molt into the adult stage and produce two pairs of egg clusters. The female *Salmincola* dies shortly after the second group of eggs hatch.

V. Diagnosis

Salmincola are large enough to observe grossly. Visual examination of fish skin, fins, gills and mouth can reveal the extent of copepod infestation. Microscopic examination of various morphological characteristics aid in identifying the parasite to the genus and species.

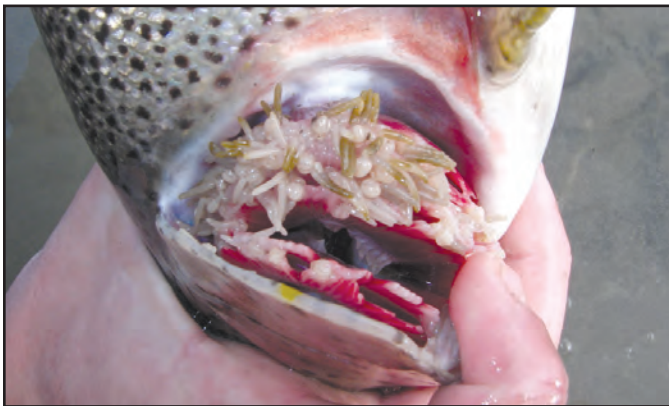
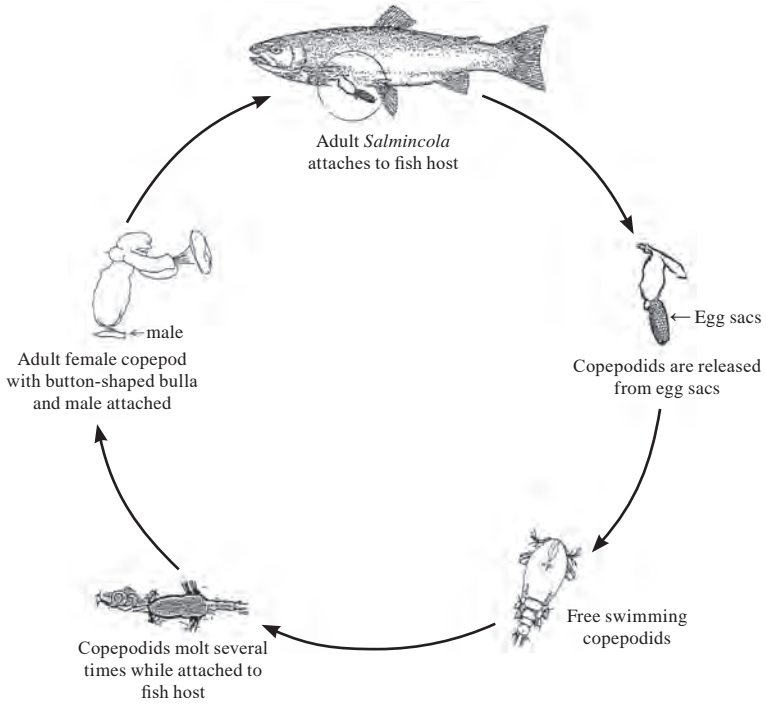
VI. Prognosis for Host

Prognosis for the host is good when infestations are not severe and damage to gill tissue is minimal. Generally, infestations with this parasite do not cause significant fish mortality.

VII. Human Health Significance

There are no human health concerns associated with *Salmincola*.

Salmincola Life Cycle



Severe *Salmincola* infestation of rainbow trout gills; note necrotic areas at tips of gill lamellae.