

Pacific Salmon Paramyxovirus

I. *Causative Agent and Disease*

Pacific salmon paramyxovirus (PSPV) is a large, irregular shaped, enveloped, single-stranded RNA virus about 125-250 nm in diameter belonging in the family Paramyxoviridae and the genus *Aquaparamyxovirus*. The virus is of low virulence and not associated with disease or mortality. The viral agent is generally isolated from asymptomatic carrier fish during routine viral screening.

II. *Host Species*

The most common host in North America is adult Chinook salmon from Alaska, Oregon and Washington. Unconfirmed isolates have been reported from other salmonids. In Norway, Atlantic salmon paramyxovirus (ASPV) has been isolated from seawater reared Atlantic salmon.

III. *Clinical Signs*

No clinical signs of disease are associated with fish infected by PSPV. The ASPV paramyxovirus in Norway is reportedly associated with the disease syndrome, proliferative gill inflammation (PGI).

IV. *Transmission*

The mode of transmission is horizontal by water or fish to fish. A marine reservoir for the virus is suspected.

V. *Diagnosis*

Detection of paramyxovirus is by isolation in cultures of susceptible fish cell lines inoculated with infected tissue. The virus causes a cytopathic effect (CPE) characterized by retracted and rounded cells after an extensive incubation period. Presumptive identifications are made by observing the typical CPE.

This virus has the unique characteristic among fish viruses of hemagglutinating erythrocytes from fish, some mammals (human, rabbit, horse, guinea pig and swine), and birds. Hemagglutination allows viral placement in the Paramyxoviridae and confirmation of a paramyxovirus along with other procedures including ultrastructural morphology by electron microscopy, fluorescent antibody testing (FAT), PCR and sequencing.

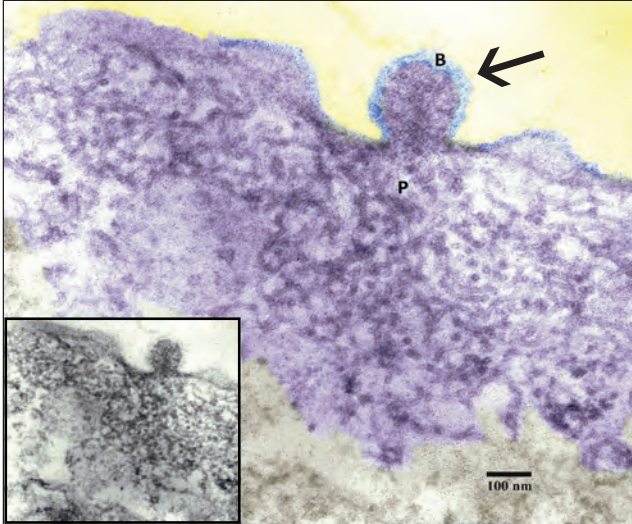
VI. *Prognosis for Host*

The prognosis for the host is good regarding the non-pathogenic nature of the North American isolates of PSPV. The role of Norwegian ASPV in causing PGI is questionable since other agents have been present confounding the true etiology of fish mortality. In this case perhaps corrective therapy would include optimizing the environment and avoidance. Further study is warranted.

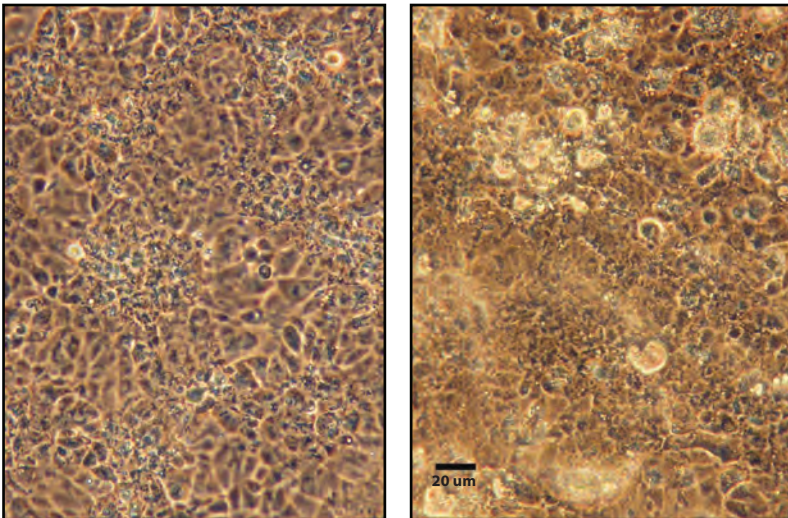
VII. *Human Health Significance*

There are no human health concerns associated with paramyxoviruses in fish.

VIRUSES



Chinook salmon, Ninilchik River, AK. Falsely colored ultrastructure of PSPV in cultured infected CHSE-214 cell with three virus particles in different stages of budding from cell membrane (arrow = center particle); blue (B) = spiked envelope; purple (P) = nucleocapsid within particles from pool of subsurface nucleocapsid material in the cytoplasm. **Inset:** Same image not colorized. (From Meyers and Batts 2016).



Cytopathic effect of PSPV from Chinook salmon, Ninilchik River, AK in CHSE-214 cells at 14°C demonstrating clustered rounding and refractility of cells (**Right**) at 9 days post-inoculation of previously passaged material. Normal cell culture (**Left**). Phase contrast (From Meyers and Batts 2016).