

Anisakid Larvae

I. Causative Agent and Disease

The larval form (third stage juvenile) of several nematode species within the subfamily Anisakinae are found coiled in the flesh and viscera of parasitized fish. Common genera include *Anisakis*, *Paranisakis*, *Porrocaecum*, *Pseudoterranova* and *Contracaecum*. The larvae are relatively non-pathogenic to the fish host, although visceral adhesions from migrating larval worms do occur.

II. Host Species

Anisakid larvae are common in marine and anadromous fishes worldwide and have also been reported in squid and cuttlefish. In Alaska, among other fish species, these worms are commonly found in Pacific salmon and cod, walleye pollock, Pacific halibut and Pacific herring (herring worm).

III. Clinical Signs

Parasitized fish contain reddish or white, tightly coiled larval worms found most commonly in skeletal muscle and visceral organs. These areas may exhibit mild inflammation, encapsulation and/or granuloma formation. Visceral adhesion may occur in fish when many juvenile worms are present in the visceral cavity. This condition causes production of fibrous connective tissue by the fish host in response to irritation from migrating worms.

IV. Transmission

Anisakid worms have a complex life cycle involving several hosts. Eggs eliminated in the feces from the final host hatch in the sea where the larvae are consumed by crustaceans (usually Euphausiids), which in turn are eaten by fish. The larva burrows into the gut or flesh of the fish and encysts until its life

cycle is completed when ingested by the final host, usually a marine mammal but sometimes a bird or fish. Incidental parasitism of a human host usually results in re-encystment of the juvenile worm. The nematode matures in the gut of the marine mammal host and releases eggs into the sea to continue the cycle. Some anisakid larvae can also be transmitted from fish to fish through predation.

V. Diagnosis

Presumptive diagnosis is made by visual examination of the body cavity, organs and flesh of the fish for typical coiled worms. Examination under a dissecting microscope can verify the identity of the larval nematodes based on morphological characteristics. PCR has been useful in confirming species that has resulted in changing taxonomy.

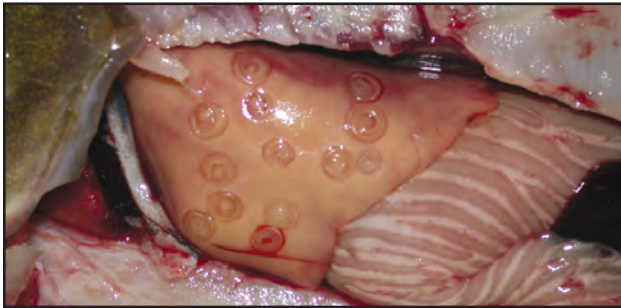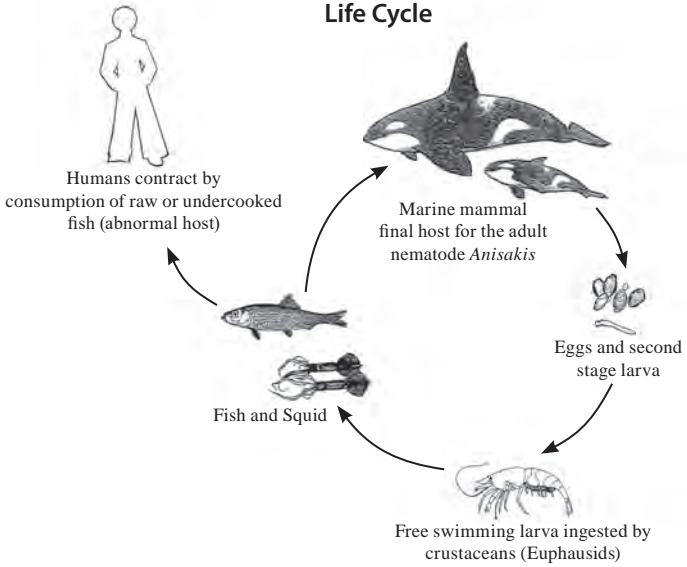
VI. Prognosis for Host

Prognosis for the fish host is good. In most cases the worms are well tolerated and there have been few reported cases of fish mortality due to juvenile anisakid parasitism.

VII. Human Health Significance

Anisakiasis in humans can be acquired by eating viable worms in raw or partially cooked fish. The Food and Drug Administration recommends cooking fish at 67°C for 5 minutes or freezing at -20°C for at least 7 d before eating to kill juvenile anisakid worms.

Anisakis Life Cycle



Anisakis third stage juvenile worms tightly coiled in liver.



Anisakis third stage juvenile worm being pulled from salmonid muscle.