

# Hexamita

---

## I. Causative Agent and Disease

### *Hexamita (nelsoni and inflata)*

is a zooflagellate protozoan that is a free-living saprophyte occurring in the vicinity of oyster beds. It can become a facultative parasite when environmental conditions are unfavorable or may become a secondary pathogen of oysters dying from other diseases. *Hexamita* is commonly found in low numbers within the intestinal tract of oysters with no associated pathology.

## II. Host Species

*Hexamita* can be found associated with several different species of oysters worldwide. It has been associated with mortality of the native oyster in winter during cold seawater temperatures in Puget Sound, Washington and mortality of the European flat oyster in recirculating seawater pits (Pit Disease) in the Netherlands. *Hexamita* sp. has been detected once in southeast Alaska during 1987 as a secondary pathogen associated with opportunistic bacteria contributing to summer mortality in 18 month-old Pacific oysters stressed by high seawater temperatures and rapid gonadal development.

## III. Clinical Signs

Diseased oysters have no specific gross clinical signs but hemolymph smears may contain large numbers of the flagellate while systemic infestation by the parasite is evident in all tissues by histological examination.

## IV. Transmission

The mode of transmission is horizontal since *Hexamita* sp. occurs as a saprophyte in ambient seawater and as part of the normal gut flora of healthy oysters.

## V. Diagnosis

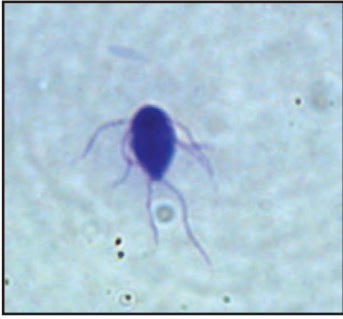*Hexamita*, as observed in hemolymph smears or tissue squashes, is very motile and pyriform in shape, about 14-17  $\mu\text{m}$  long by 7-10  $\mu\text{m}$  wide and has 6 anterior and 2 posterior flagella. Mixed populations of bacterial rods may also be present in the hemolymph of moribund or dead oysters. Histological examination demonstrates the protozoan in gut lumens of healthy animals. In diseased animals the organism is present on mantle and gill surfaces and throughout all tissues as are various bacteria and tissue necrosis. *Hexamita* can be cultured in artificial media and in filtered seawater containing antibiotics. Identification of the organism to species requires silver impregnation stains to reveal distinguishing morphological characteristics.

## VI. Prognosis for Host

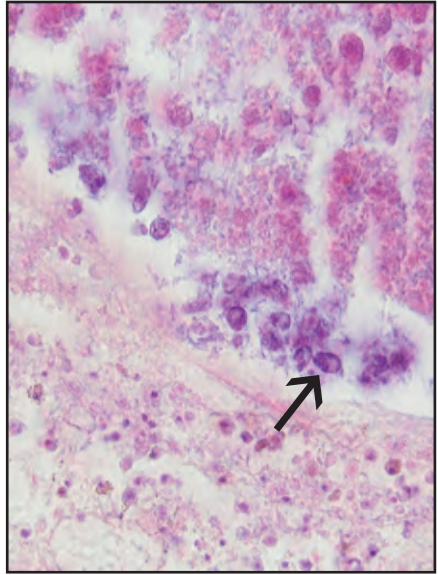
*Hexamita* may be found at low intensities and generally does not invade the tissues of healthy oysters except when poor or extreme environmental conditions (high temperatures, low temperatures  $< 6^{\circ}\text{C}$ , poor water quality) cause physiological stress. In such cases, overwhelming systemic disease can occur with reported mortality greater than 50% in Alaskan Pacific oysters and up to 75% in native oysters from Puget Sound, Washington.

## VII. Human Health Significance

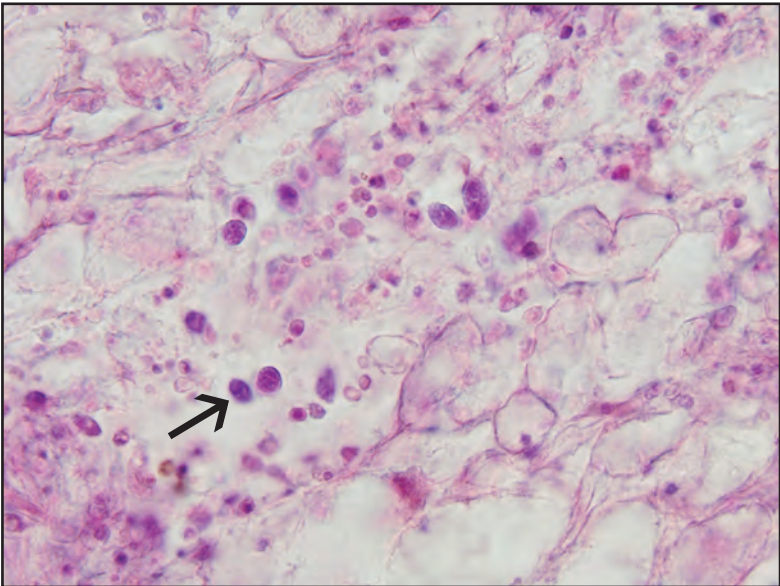
There are no zoonotic human health concerns regarding the presence of *Hexamita* in oyster tissues.



*Hexamita* sp. in a Giemsa stained smear



Histological section of *Hexamita* sp. (arrow) within the intestine of Pacific oyster associated with a bacterial infection



Histological section of *Hexamita* sp. (arrow) within the connective tissues of Pacific oyster