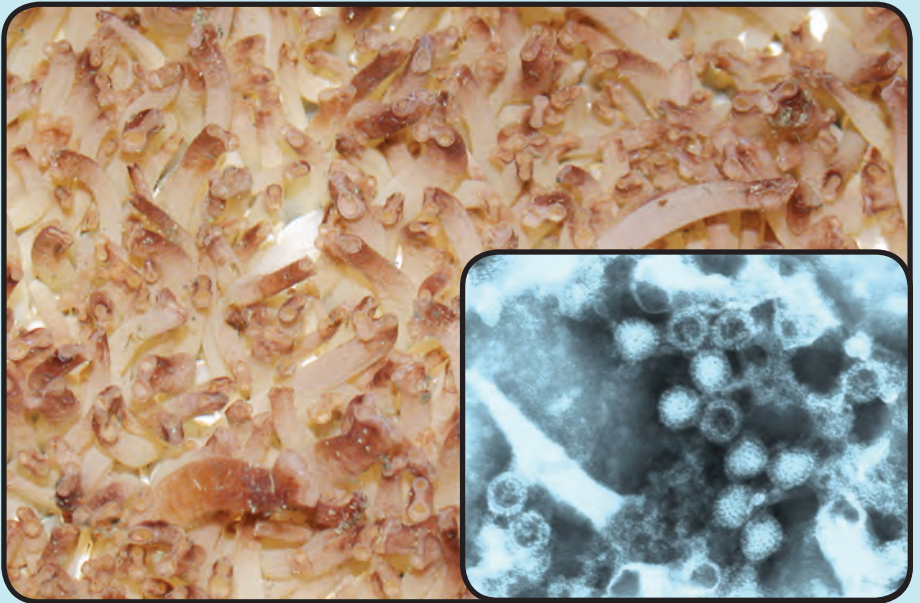


DISEASES OF WILD AND CULTURED SHELLFISH IN ALASKA



Theodore Meyers and Tamara Burton

February 2009

Alaska Department of Fish and Game

Fish Pathology Laboratories



The Alaska Department of Fish and Game
printed this publication at a cost of \$12.47
in Anchorage, Alaska, USA.

About This Booklet

The overwhelming success of the 2007 publication “Common Diseases of Wild and Cultured Fishes in Alaska” encouraged our publication of a companion book describing the common and not so common diseases of shellfish in Alaska. This book is a brief illustrated guide that describes many of the parasitic, infectious, and noninfectious diseases of bivalve molluscs and crustaceans encountered in Alaska. The content is directed towards lay users, as well as aquaculturists and biologists and is not a comprehensive treatise nor should it be considered a scientific document. Interested users of this guide are directed to the listed shellfish disease references for additional information.

Information contained within this booklet is published from the laboratory records of the Alaska Department of Fish and Game, Fish Pathology Section that has regulatory oversight of shellfish health in the State of Alaska.

Alaska Department of Fish and Game, Fish Pathology Laboratories, 333 Raspberry Road, Anchorage, Alaska 99518; 3333 Glacier Highway, Juneau, Alaska 99802.

Manuscript Photographs: Alaska Department of Fish and Game, Fish Pathology Laboratory photo archives except where indicated by photo credits

Cover Photographs: Cultured juvenile geoduck clams at Alutiiq Pride Shellfish Hatchery, Seward, Alaska and (inset) negative stain of *Aquareovirus* isolated from wild adult geoduck clams

©2009 Alaska Department of Fish and Game



The Alaska Department of Fish and Game (ADF&G) administers all programs and activities free from discrimination based on race, color, national origin, age, sex, religion, marital status, pregnancy, parenthood, or disability. The department administers all programs and activities in compliance with Title VI of the Civil Rights Act of 1964, Section 504 of the Rehabilitation Act of 1973, Title II of the Americans with Disabilities Act of 1990, the Age Discrimination Act of 1975, and Title IX of the Education Amendments of 1972. If you believe you have been discriminated against in any program, activity, or facility please write ADF&G ADA Coordinator, P.O. Box 115526, Juneau, AK 99811-5526; U.S. Fish and Wildlife Service, 4401 N. Fairfax Drive, MS 2042, Arlington, VA 22203; or Office of Equal Opportunity, U.S. Department of the Interior, 1849 C Street NW MS 5230, Washington DC 20240.

For information on alternative fomats and questions on this publication, please contact the department's ADA Coordinator at (VOICE) 907-465-6077, (Statewide Telecommunication Device for the Deaf) 1-800-478-3648, (Juneau TDD) 907-465-3646, or (FAX) 907-465-6078.

Table of Contents

Bivalve Molluscs

Viruses

<i>Aquabirnavirus</i>	2
<i>Aquareovirus</i>	4
Gametogenic Hypertrophy.....	6
<i>Herpesvirus</i>	8

Bacteria

Bacterial Septicemia - <i>Vibrio</i> and Others.....	10
Nuclear Inclusion X.....	12
Pacific Oyster Nocardiosis.....	14
Prokaryotic Intracytoplasmic Inclusions.....	16

Fungi

Shell Fungus.....	18
Systemic Mycosis.....	20

Protozoa

Gill and Gut Ciliates.....	22
<i>Haplosporidium</i> sp.....	24
<i>Hexamita</i>	28
<i>Ichthyobodo</i> -like Protozoan.....	30
<i>Nematopsis</i> and Other Gregarines.....	32
<i>Steinhausia</i> and Other Microsporidia.....	34
Trichodinid Ciliates.....	36
Unidentified Kidney Coccidia and Others.....	38

Helminths

Gill and Gut Turbellaria.....	44
Shell-boring Polychaetes.....	46
Trematode Metacercariae and Sporocysts.....	48

Arthropods

Gill and Gut Parasitic Copepods.....	52
--------------------------------------	----

Miscellaneous

Foreign Body Granulomas and Pearls.....	56
Miscellaneous Invertebrate Pests and Pedators.....	58
Neoplasia.....	62

Crustaceans

Viruses

Aquabirna and Herpes Viruses.....	66
-----------------------------------	----

Bacteria

Prokaryotic Intracytoplasmic Inclusions.....	70
Shell Disease.....	74

Fungi

Black Mat Syndrome.....	76
Fungal Infection of Captive Red King Crabs.....	78

Protozoa

Haplosporidian-like Parasite of Shrimp.....	80
<i>Hematodinium</i> - Bitter Crab Disease.....	84
<i>Hematodinium</i> -like Disease Dungeness Crabs.....	90
<i>Mesanothryx</i> sp. Ciliate Disease.....	92
<i>Thelohania</i> and Other Microsporidia.....	94

Helminths

<i>Carcinonemertes</i> Egg Predator.....	98
Crab Leech.....	102
Encysted Trematode Metacercariae.....	104
Trypanorhynch Cestode Plerocercoids.....	106

Arthropods

<i>Briarosaccus callosus</i> - Parasitic Barnacle.....	108
--	-----

Miscellaneous

Digestive Tubular Degeneration and Bio-Foul.....	112
Idiopathic Granulomatosis - Dungeness Crab.....	114
Proliferative Lesions and Neoplasia.....	116

Reference

Glossary of Terms.....	120
Shellfish Disease References.....	127

Aquabirnavirus

I. Causative Agent and Disease

Aquabirnavirus is a recent new genus in the virus family Birnaviridae. These unenveloped icosahedral (~60 nm) viruses (over 200 isolates) contain a bi-segmented double stranded RNA genome that encodes 5 proteins and have been isolated in cell culture from a variety of marine and freshwater fish and shellfish species worldwide. There are three and possibly four serogroups (A, B, C & D) comprising at least 16 serotypes of aquabirnaviruses. Molecular testing has determined there are currently 7 genogroups. Several of these viruses occurring in finfish cause disease (such as IPNV in salmonids) while those infecting molluscs are mostly apathogenic, although some isolates have been reported to cause cell pathology or mortality in stressed bivalves. Some of these viruses that are shed into the water column by a fish host may be bioaccumulated by nearby bivalve molluscs through the filter feeding mechanism. These viral agents in shellfish are most often isolated from asymptomatic adult animals during routine virus screening examinations.

II. Host Species

Currently, aquabirnaviruses have been isolated from many different fish and shellfish species including 32 families of finfish, 11 species of bivalve molluscs and at least 4 species of crustaceans. In Alaska, *Aquabirnavirus* has been isolated in fish cell lines from asymptomatic adult littleneck clams and an aquabirnavirus-like agent has been observed by transmission electron microscopy in a male blue king crab associated with an adenocarcinoma-like proliferative lesion (discussed in the crustacean section).

III. Clinical Signs

Bivalve molluscs are generally asymptomatic carriers and/or vectors of these viruses.

IV. Transmission

Transmission is horizontal animal to animal via water. Isolates from bivalve molluscs may also represent bioaccumulation from filter feeding after the virus is shed into the water column from a nearby fish host.

V. Diagnosis

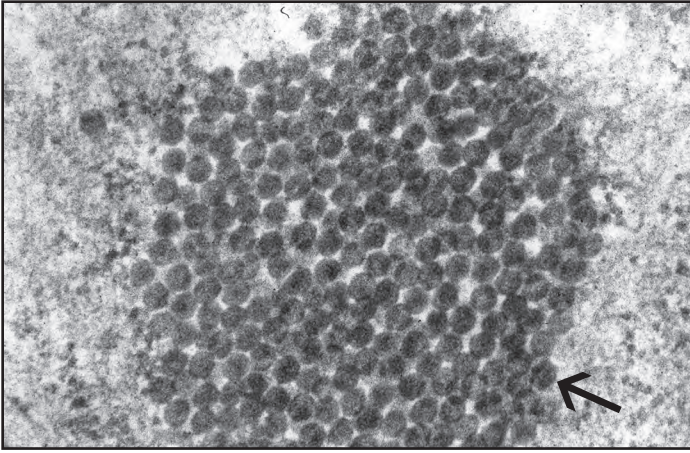
Detection of *Aquabirnavirus* is accomplished either by direct examination of shellfish tissues with transmission electron microscopy (TEM) or by isolating the virus in cultures of susceptible fish cell lines that have been inoculated with contaminated or infected shellfish tissue. Cytopathic effect (CPE) is generally a nondescript diffuse thinning and necrosis of infected cells. Identification is based on serology and TEM or by polymerase chain reaction (PCR). There are no established bivalve mollusc or crustacean cell lines for isolating viruses that may have a strict host specificity for shellfish, although there has been some success in culturing primary cell monolayers from certain shellfish species.

VI. Prognosis for Host

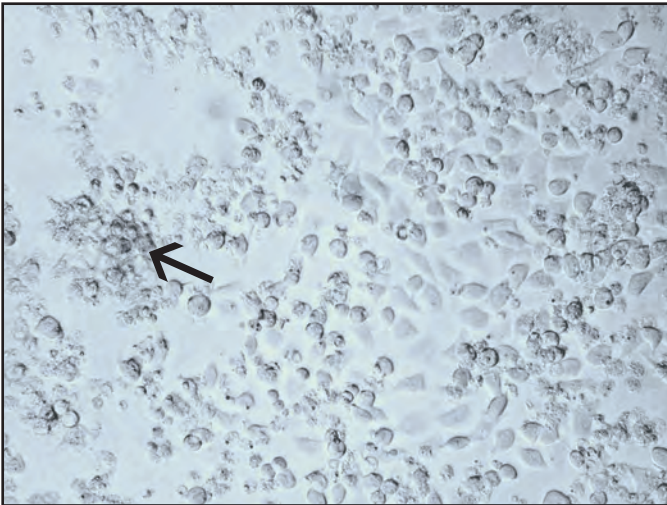
Bivalve molluscs are asymptomatic carriers and/or vectors of these viruses.

VII. Human Health Significance

There are no zoonotic human health concerns associated with aquabirnaviruses in shellfish.



TEM of cultured bluegill fry cell with cytoplasmic aggregate of hexagonal-shaped aquabirna-like virus particles (arrow) isolated from littleneck clams



CPE in CHSE-214 cells showing areas of cell rounding and necrosis (arrow) typical of *Aquabirnavirus*

Aquareovirus

I. Causative Agent and Disease

Aquareovirus is a recent new genus in the virus family Reoviridae. These icosahedral (60–80 nm) double-stranded RNA viruses (over 50 isolated) with 11 genome segments have been isolated in cell culture from a variety of marine and freshwater aquatic animals worldwide including finfish and bivalve molluscs. There are several reports of reo-like viruses observed in crustaceans but these viruses have fewer or more genome segments and most have not been cultured. Genetic analyses have identified 7 (A, B, C, D, E, F, G) different genotypes of aquareoviruses. Except for isolates reported from 7 fish species, most of these viruses produce self-limiting infections of low pathogenicity in fish that are not associated with extensive disease or mortality. In bivalve molluscs these viruses are most likely bioaccumulated by the filter feeding mechanism. These viral agents in shellfish are most often isolated from asymptomatic adult animals during routine virus screening examinations.

II. Host Species

Currently, aquareoviruses appear to be mostly of finfish origin with a wide host range of marine and freshwater species. In Alaska, *Aquareovirus* has been isolated from ovarian fluids of returning chinook salmon (genotype F) and adult geoduck clams (genotype A). Because aquareoviruses appear to be widespread in many fish host species, it is likely other bivalve mollusc species in Alaska may bioaccumulate these viruses from marine fish. Other isolates of aquareovirus (13p2) from bivalve molluscs have been reported from eastern oysters in waters off Long Island, New York.

III. Clinical Signs

Fish and bivalve molluscs are generally asymptomatic carriers and vectors, respectively, of the virus.

IV. Transmission

Transmission is horizontal via water. Isolates from bivalve molluscs likely represent virus bioaccumulated by filter feeding after the virus is shed into the water column from a nearby fish host.

V. Diagnosis

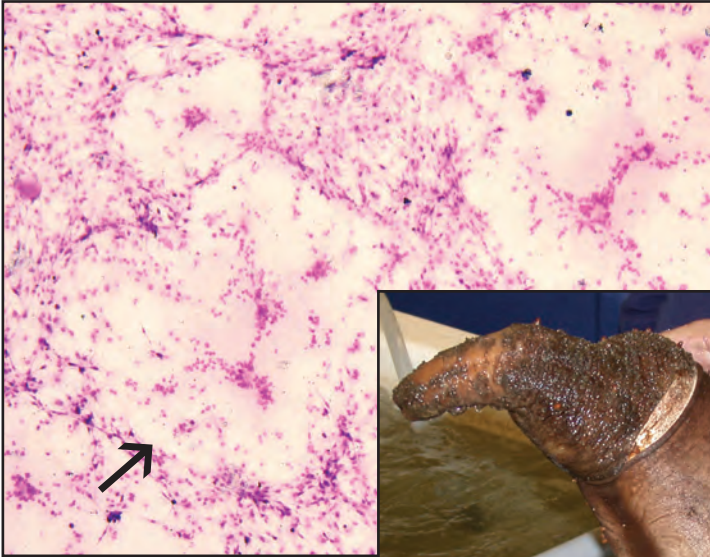
Detection of aquareoviruses is accomplished by isolating the virus in cultures of susceptible fish cell lines that have been inoculated with contaminated shellfish tissue. Nearly all of these viruses cause a unique cytopathic effect (CPE) characterized by focal areas of cellular fusion (syncytia) and cytoplasmic destruction creating a vacuolated or foamy appearance. An exception is the grass carp *Aquareovirus* that produces a diffuse CPE. Presumptive identifications are based on the typical CPE and confirmed serologically, by electron microscopy or by polymerase chain reaction (PCR). There are no established bivalve mollusc or crustacean cell lines for isolating viruses, although there has been some success in culturing primary cell monolayers from certain shellfish species.

VI. Prognosis for Host

Bivalve molluscs are asymptomatic vectors of the viruses which are transiently present in the water column.

VII. Human Health Significance

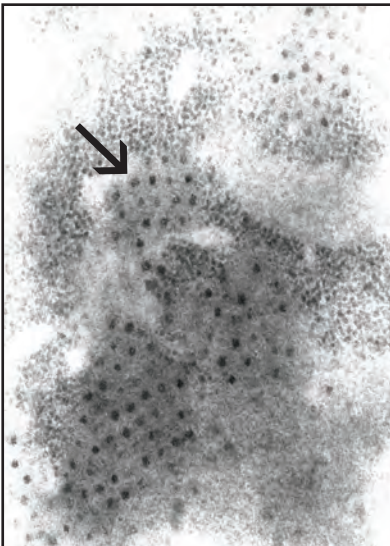
There are no zoonotic human health concerns associated with aquareoviruses.



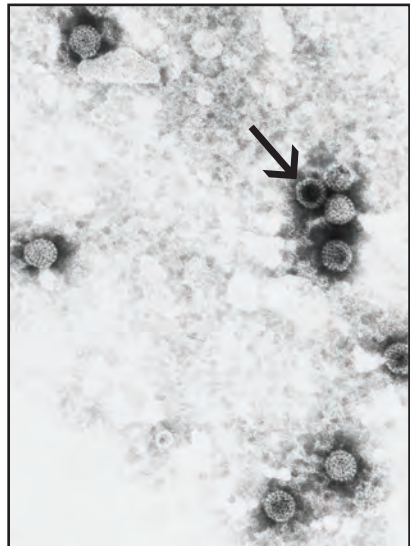
Stained focal area of syncytial CPE (arrow) of geoduck *Aquareovirus* in bluegill fry cells.



Adult geoduck clam, a vector species for *Aquareovirus* in Alaska.



TEM showing cytoplasmic arrays of geoduck *Aquareovirus* particles (arrow) in cultured bluegill fry cell



Negative stain of virus particles (arrow) showing double capsid morphology

Gametogenic Hypertrophy

I. Causative Agent and Disease

Gametogenic hypertrophy is caused by an unclassified papilloma-like or polyoma-like virus previously referred to as papovavirus. The virus is icosahedral, non-enveloped, about 40-50 nm in diameter and is likely composed of double-stranded DNA. The virus infects the nuclei of developing gametogenic cells in both male and female oysters and clams causing extreme cell enlargement (hypertrophy) first observed in female ova, hence referred to as "ovacystis". The number of hypertrophied gametocytes per animal is generally low and the condition appears to have very little pathological significance to the host animal.

II. Host Species

Ovacystis has been reported from the east, west and gulf coasts of North America, France, Germany, Korea, Australia and Spain in at least seven oyster species and two clams, the Manila and soft shell. In Alaska and the Pacific Northwest, ovacystis has been observed at very low prevalences in both male and female adult Pacific oysters.

III. Clinical Signs

There are no outward clinical signs of disease. The condition is found incidentally during routine histological examination of apparently healthy Pacific oysters.

IV. Transmission

Transmission has not been established but presumably it is horizontal from animal to animal via ambient seawater. However, vertical transmission to progeny from infected parents may also be possible.

V. Diagnosis

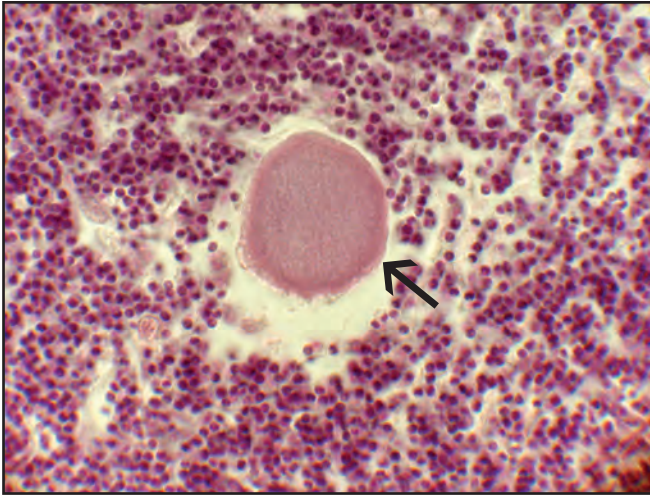
Occasional extreme nuclear hypertrophy of male or female gametocytes is observed by histological examination. Presence of virus particles having the typical size and morphology within the enlarged nuclei can be confirmed by transmission electron microscopy (TEM). There are no bivalve mollusc cell lines, therefore the virus has not been cultured.

VI. Prognosis for Host

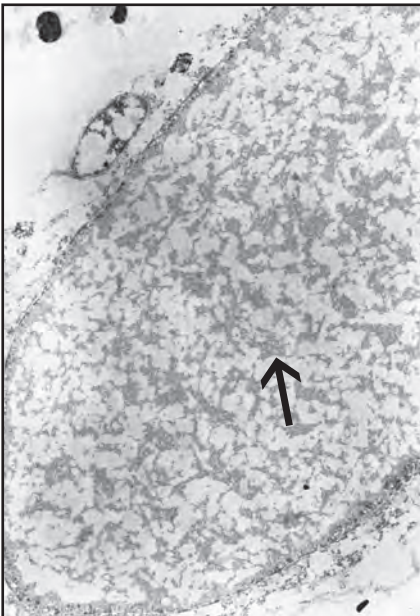
The condition caused by the virus results in no mortality or apparent harm to the host animal.

VII. Human Health Significance

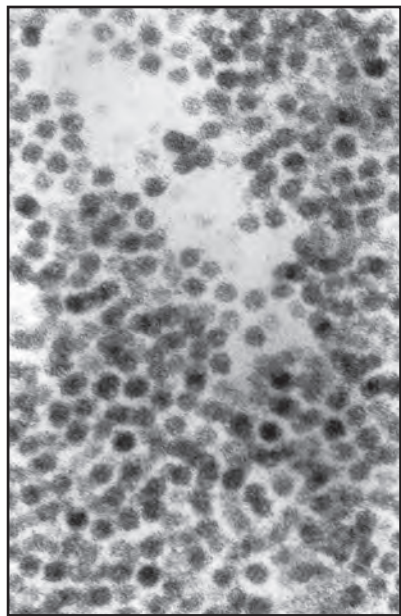
There are no zoonotic human health concerns regarding gametogenic hypertrophy in bivalve molluscs.



Histological section of enlarged gametocyte nucleus (arrow) in male Pacific oyster



Ultrastructural section of enlarged nucleus containing arrays of virus-like particles (arrow)



Higher magnification of virus particles

Herpesvirus

I. Causative Agent and Disease

Herpesviruses are icosahedral, quasi-spherical viruses that have a lipid envelope. They are members of the family Herpesviridae and contain a genome of linear double stranded DNA with a particle size of 102-200 nm in diameter. There are approximately 120 herpesviruses infecting a wide range of vertebrates and invertebrates including marine bivalve molluscs. Herpesviruses can be serious pathogens of hatchery reared juvenile oysters and clams while significant mortality in nature may require the presence of environmental stressors.

II. Host Species

Herpes and herpes-like viruses have been reported worldwide in several bivalve mollusc species in North America, Mexico, Europe, South America, Australia, New Zealand and Asia. Infected bivalve hosts include 7 species of cupped and flat oysters, Manila clam, carpet shell clam and French scallop. In Alaska, herpesvirus-like particles associated with Cowdry Type A intranuclear inclusion bodies have been observed by transmission electron microscopy (TEM) in mantle epithelium of rock scallops and in the digestive gland epithelium of native littleneck clams from several sites throughout the state. Typical inclusion bodies have also been observed in the mantle epithelium of juvenile Pacific oysters from the southeast panhandle. Because herpesviruses in vertebrates are typically very host specific, bivalve herpesviruses may be comprised of several different genotypes. However, at least one virus, OsHV1, is capable of infecting several bivalve species.

III. Clinical Signs

Juvenile animals may exhibit slow or no growth with high mortality approaching 100% when seawater temperatures are 25-26°C. Infection is usually associated with intranuclear inclusion bodies and necrosis of host cells including connective tissues of the gills, interstitial cells around the digestive gland, epithelium of the mantle and the velar epithelium and hemocyte precursor cells in larvae. Occasional secondary bacterial infection of larvae and seed may further contribute to the severity of the mortality and confound the true etiology. However, no mortality of wild or cultured bivalve molluscs in Alaska has yet been associated with a herpesvirus infection.

IV. Transmission

Transmission is horizontal from animal to animal via ambient seawater or vertical transmission to progeny from infected parents.

V. Diagnosis

Diagnosis is based on histological observation of margined chromatin and eosinophilic Cowdry Type A inclusion bodies within hypertrophied nuclei of infected cells, although this cytopathology is not always present. Association of typical virus particles in infected cells is confirmed with TEM and PCR primers for certain strains of the virus are available for definitive identification. There are no bivalve cell lines available to culture these viruses which will not replicate in the existing cell lines that are available.

VI. Prognosis for Host

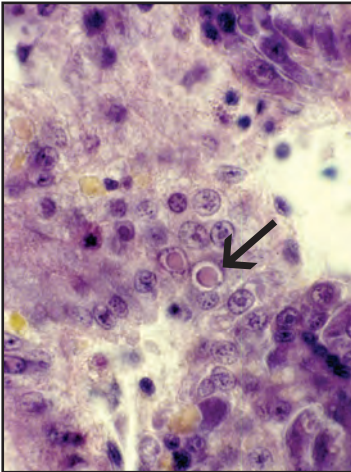
There is no treatment for systemic

virus infections except avoidance and prevention of virus introduction with infected shellfish stocks. Herpesvirus infection may result in high mortality of juvenile bivalve molluscs. Juvenile survivors and exposed adult animals become carriers of latent virus which may cause additional mortality during periods of stress and seawater temperature extremes. Seawater temperature has been lowered to reduce juvenile mortality in certain cultured bivalve species

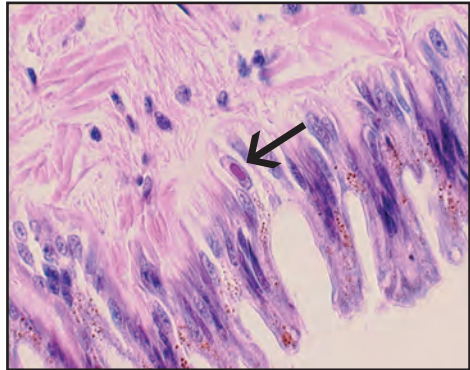
or spat deployment to infected culture areas has been avoided during periods of high seawater temperatures. In Alaska, optimum seawater temperatures for virus replication and high mortality may only occur in rare circumstances.

VII. Human Health Significance

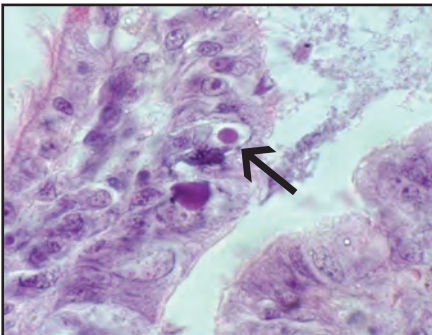
There are no zoonotic human health concerns regarding herpesvirus infections of bivalve molluscs.



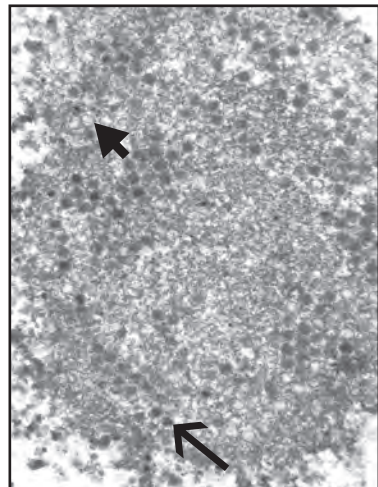
Histological section of Cowdry Type A intranuclear inclusion bodies (arrow) in the digestive epithelium of littleneck clam



Histological section of inclusion body (arrow) in the mantle epithelium of purple-hinged rock scallop



Histological section of intranuclear inclusion bodies in the mantle epithelium of Pacific oyster



Ultrastructural section of a Cowdry Type A inclusion body in a digestive tubule epithelial cell from littleneck clam showing nucleocapsids (arrow) and empty capsids (arrowhead) of herpes-like virus particles

Gram-Negative Bacterial Septicemia *Vibrio* and Others

I. Causative Agent and Disease

Gram-negative bacterial septicemia, also called bacillary necrosis (when motile bacteria are involved), is the most common disease in larval and juvenile shellfish worldwide, especially for bivalve molluscs. Bacterial septicemia can occur wherever nurseries and hatcheries are operating and is indicative of poor sanitary procedures. The most common etiological agents are vibrios including *Vibrio* sp., *V. anguillarum*, *V. ordalii*, *V. tubiashii*, *V. alginolyticus*, *V. splendidus* and occasionally *Pseudomonas* sp. and marine *Flavobacteria*. The motile vibrios and pseudomonads attach and invade soft tissues causing extensive necrosis and also produce exotoxins that can damage mantle and velar tissues without direct bacterial invasion. Filamentous non-motile *Flavobacteria* can invade the hinge ligament (hinge ligament disease) causing liquefaction, necrosis and loss of hinge function allowing secondary infections by other bacteria.

II. Host Species

All species of cultured juvenile bivalve molluscs worldwide are likely susceptible to bacterial septicemia which may also occur in adult animals when poor environmental conditions are present or when animals are otherwise stressed. Occurrence in nature has been reported but the extent is unknown. In Alaska, occasional bacterial infections of juvenile bivalves has occurred at the shellfish hatchery in Seward. Also, a mortality of adult pink neck surf clams near Juneau was associated with a marine flavobacterial septicemia when clams were stressed by very warm sunny weather during minus tides.

III. Clinical Signs

Clinical signs of bacterial septicemias include slow growth, failure to set, high morbidity with reduced movement and mortality of larval and juvenile bivalves associated with attached or swarming bacteria. Tissues become necrotic and may detach into the water column.

IV. Transmission

These bacteria are normal marine flora. Transmission is horizontal via incoming seawater, contaminated algal food stocks and from brood stocks or otherwise infected animals.

V. Diagnosis

Numerous Gram-negative, motile bacteria in wet mounts of dead or dying larvae and tissues of larger juvenile bivalves provide a presumptive diagnosis. Histological sections demonstrate invasive bacteria in soft tissues and flavobacteria in hinge ligaments. Definitive diagnosis of specific bacteria is based on isolation and biochemical characterization, fluorescent antibody tests or PCR.

VI. Prognosis for Host

Bacterial septicemia in larvae and juvenile bivalve molluscs generally results in high mortality. Management of the disease is based on enhanced hatchery and nursery sanitation procedures as preventative measures. Lowering of seawater temperatures below the optimum growth range of the bacteria (less than 25°C) can markedly inhibit the disease.

VII. Human Health Significance

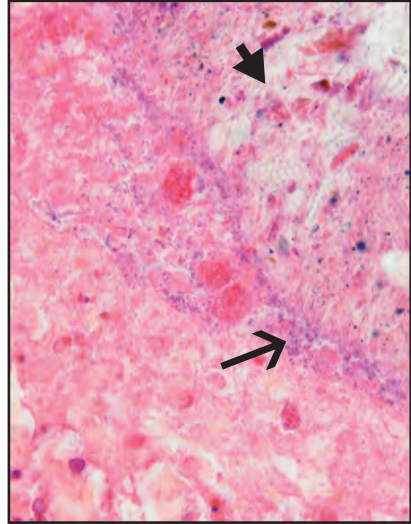
Certain vibrios and pseudomonads infecting shellfish are known to be of

human health concern. However, these bacteria in juvenile life stages that are too small for consumption are not likely

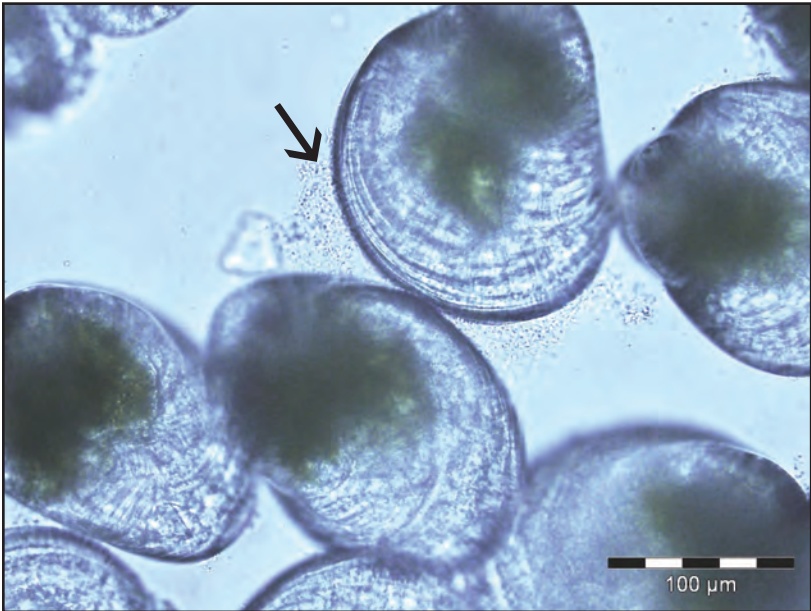to be of zoonotic human health significance.



Mortality of adult pink-necked surf clams due to flavobacterial infection during warm weather minus tides



Histological section of bacterial septicemia and necrosis of the intestinal mucosa (arrowhead) from Pacific oyster caused by Gram-negative bacteria (arrow)



Wet mount of Gram-negative bacteria (arrow) swarming around the mantle periphery of larval Pacific oysters (Photo: R. Elston, AquaTechnics, WA)

Nuclear Inclusion X

I. Causative Agent and Disease

Nuclear inclusion X (NIX) is a unique rickettsia-like organism infecting the nuclei of non-ciliated branchial epithelium in razor clam populations from Washington and Oregon. This pathogen has caused massive mortality in Washington razor clams and has possibly caused declines in clam populations in Oregon as well. The organism completes its replication cycle by rupturing infected gill epithelium causing respiratory failure and secondary infection by other opportunistic bacteria.

II. Host Species

This organism is exclusive to razor clams in Oregon, Washington and lower British Columbia, Canada. One sample of razor clams from Alaska, among two others that were negative, was found to be positive for NIX. However, the positive clams were held for about 2 months in infected state waters of Washington before they were examined. Consequently, it is very unlikely that NIX occurs in Alaska as it has not been found in other samples above Vancouver Island, BC. Nonetheless, the pathogen is included here for future reference.

III. Clinical Signs

Infected clams present with extensive swelling of branchial epithelium and enlarged nuclei within intact cells or the nuclei are floating free nearby lysed cells when examined in wet mounts. Secondary infection by other opportunistic bacteria is common. Histological examination shows massively enlarged cell nuclei enclosing the basophilic rickettsial organism within the non-ciliated respiratory epithelium of the gills.

IV. Transmission

The mode of transmission is not known but is likely horizontal via ambient seawater contaminated by nuclei from ruptured host cells each containing the parasite. The cycle of the disease appears to begin by infection occurring in late fall or early winter. The parasite is detected in the spring and early summer followed by enlargement and rupture of branchial host cells by fall and winter. This cell damage leads to secondary bacterial infection and death of the clams. There may also be other life stages that are infectious that have not been described and alternate reservoir hosts or vectors.

V. Diagnosis

Diagnosis is made by wet mounts and histological examination demonstrating enlarged branchial cell nuclei with typical intranuclear inclusions containing the parasite (average 21 X 13 μm in diameter). Transmission electron microscopy confirms the morphology of the parasite as rickettsia-like which is unique regarding its exclusive intranuclear occurrence during all observed life stages and its size that is larger than any known bacterium.

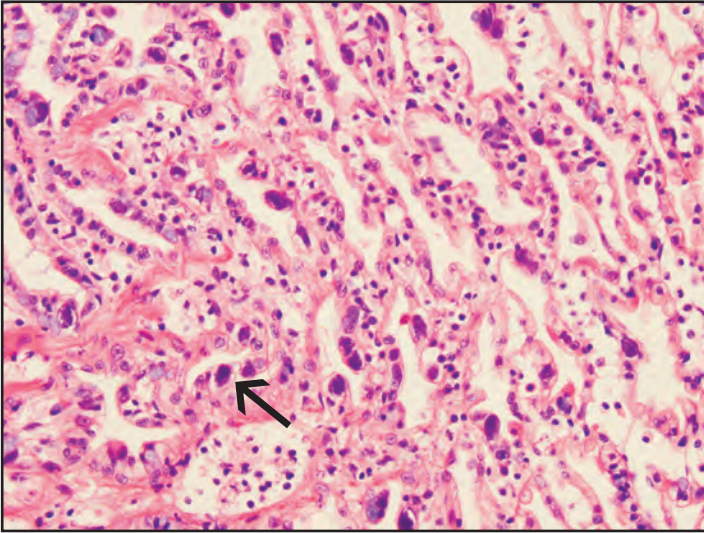
VI. Prognosis for Host

The organism has been found where populations of razor clams in Washington have undergone extreme declines of as much as 95% during 1983-1984 and 1985-1986. This may have been peak proliferative periods in the parasite life cycle, possibly influenced by unknown marine environmental conditions. Although some populations of razor clams appear to survive low intensity infec-

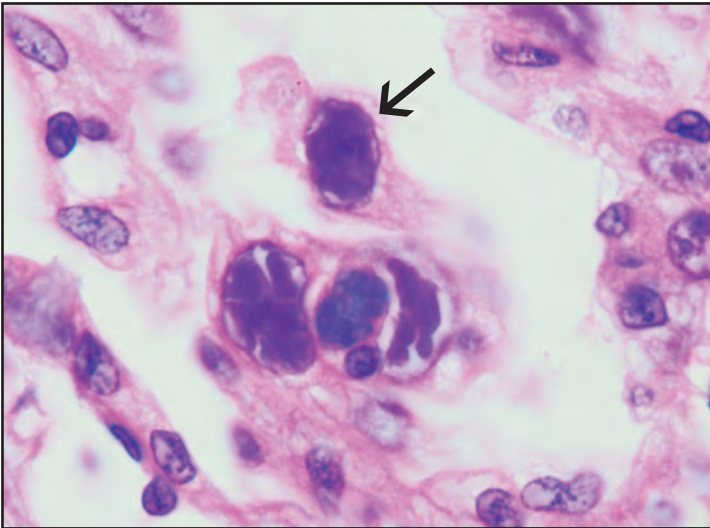
tions, the parasite has a proven potential to cause very significant population declines for reasons that are not well understood.

VII. Human Health Significance

There are no known zoonotic human health concerns regarding NIX infections in razor clams.



Histological section of NIX-infected gill epithelium (arrow) of razor clam



Histological section of inclusion bodies within enlarged nuclei (arrow) of NIX infected cells

Pacific Oyster Nocardiosis

I. Causative Agent and Disease

Pacific oyster nocardiosis (PON), previously known as “focal necrosis” and “fatal inflammatory bacteremia” (FIB) is caused by an actinomycete bacterium *Nocardia crassostreae* that is Gram-positive or Gram variable, acid fast, PAS positive and catalase positive. The bacterium contributes to “summer mortality” of 2 year and older oysters in shallow, warm eutrophic embayments during August through November when seawater temperature is 20°C or greater. Infection produces small round yellow, green or brown vesicles of bacteria and granulomas 2 mm to 1 cm in diameter throughout oyster tissues resulting in significant mortality.

II. Host Species

This disease is reported to be restricted to Pacific oysters, although a similar disease has been observed in European flat oysters cultivated near areas of infected Pacific oysters. PON has been reported in Pacific oysters from California, Washington, British Columbia, Japan and most recently from the Netherlands. In Alaska, infection by this organism was detected in only two juvenile animals imported from the state of Washington but had been reared in Alaskan waters. Therefore, it is unclear whether the disease can spontaneously occur in the colder seawater temperatures typical of Alaskan summers.

III. Clinical Signs

Clinical signs of PON include moderate to high mortality of young adult oysters that are undergoing physiological stress from rapid gonadal development with presenting lesions of small, round, yellow, green or brown vesicles of bacteria and granulomas in the tissues.

IV. Transmission

The bacterium is considered to be an opportunistic pathogen that is widespread in the marine environment. Transmission is likely horizontal and facilitated by other physical environmental stressors.

V. Diagnosis

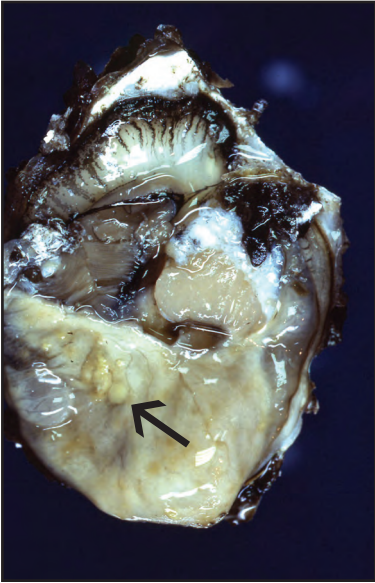
Histological examination of typical lesions in infected oyster tissues indicate Gram-positive or Gram-variable, acid fast foci of bacteria within surface vesicles and in granulomas eliciting a marked host inflammatory response. Confirmation is by fluorescent antibody staining and by transmission electron microscopy showing typical actinomycete morphology. Culture of the organism is possible on several medias for fastidious organisms but is not a routine procedure because the appearance of colony growth may take from 3 weeks to 3 months.

VI. Prognosis for Host

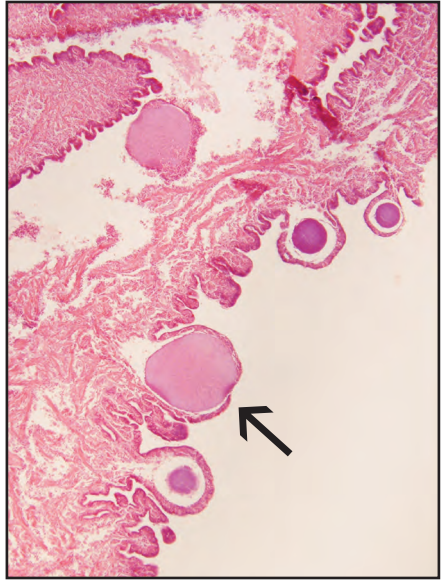
Mortality of infected oysters may be significant but has not been accurately determined in the field. However, experimental injection of the organism has produced 47-50% cumulative mortality of oysters within 30 days. Management techniques have not been investigated but culturing oysters in off-bottom gear and avoidance of shallow warm embayments in the summer may reduce the prevalence and severity of the disease.

VII. Human Health Significance

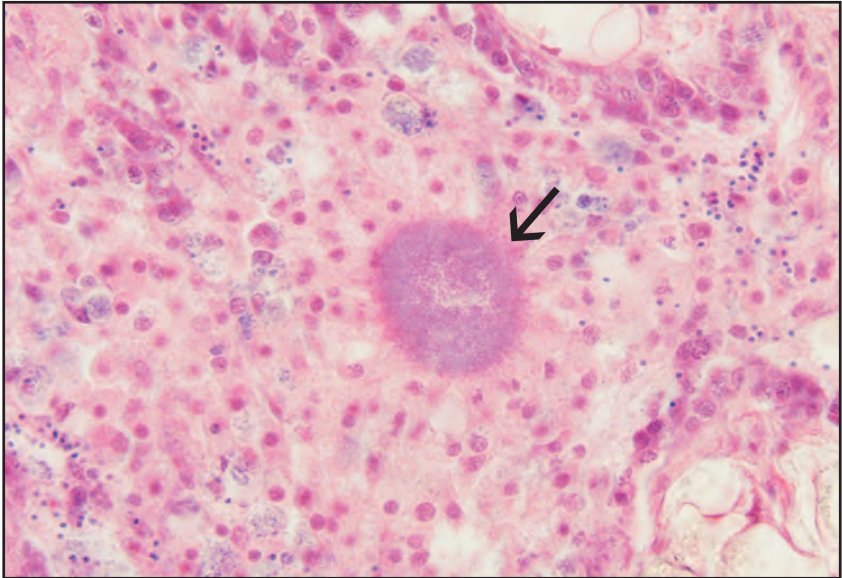
Aside from aesthetically displeasing, there are no known zoonotic human health concerns with *Nocardia* infection of Pacific oysters.



Yellow vesicles (arrow) of nocardiosis in the mantle tissues of a Pacific oyster (Photo: R. Elston, AquaTechnics, WA)



Histological section of vesicles containing bacteria (arrow) in infected mantle tissue



Typical subsurface radiating granuloma (arrow) containing central *Nocardia* organisms surrounded by host inflammatory cells, histological section

Prokaryotic Intracytoplasmic Inclusions

I. Causative Agent and Disease

Prokaryotic intracytoplasmic inclusion bodies in marine molluscs are ubiquitous having been reported globally in the epithelial cells and connective tissues of many different species. These inclusion bodies contain organisms that are mostly rickettsia-like with less reports of chlamydia-like organisms and fewer still of mollicute-like organisms or mycoplasma. In most cases these organisms are incidental infections that do not cause significant disease except most notably the rickettsial agents causing mortality of sea scallops (*Pecten maximus* and *Placopecten magellanicus*), California black and red abalones with Withering Syndrome (caused by *Candidatus Xenohaliotis californiensis*) and an intranuclear rickettsia-like organism (NIX) causing mass mortality of razor clams in Washington and possibly Oregon (discussed in other section).

II. Host Species

Numerous species of marine and some freshwater bivalve molluscs in all parts of the world have been reported with intracytoplasmic inclusion bodies caused by these intracellular bacteria. Likewise in Alaska, similar cytoplasmic inclusion bodies of rickettsia-like organisms (RLO) have been detected in: Pacific oysters; littleneck clams; razor clams; geoduck clams; butter clams; blue mussels; basket cockles; pink, rock and weathervane scallops.

III. Clinical Signs

There are no gross clinical signs of infection nor is there apparent disease. During routine histological examination round, basophilic to purple intracytoplasmic inclusion bodies are detected in

the cells of various tissues (gill, mantle, digestive gland and kidney epithelium, connective tissue, muscle and gametocytes) depending on the host species.

IV. Transmission

The mode of transmission has not been determined but could be horizontal via ambient seawater but an alternate reservoir host or vector as part of the life cycle cannot be ruled out.

V. Diagnosis

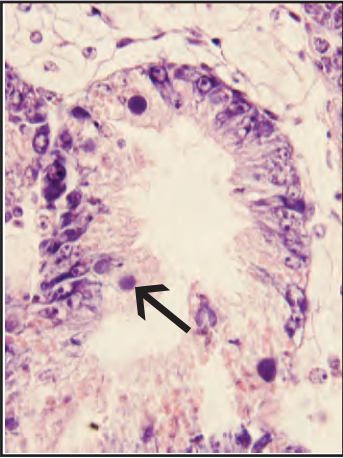
Diagnosis is by histological examination to detect the typical intracytoplasmic inclusion bodies within the cells of host tissues. Specific identification of the type of prokaryote within the inclusion bodies is based on the morphological features specific for rickettsia, chlamydia or mycoplasma as observed by transmission electron microscopy (TEM). Fluorescent antibody tests are available for some of these agents, although none have been isolated in culture using conventional methods. Only rickettsia-like organisms have been observed by TEM in the inclusion bodies found in Alaskan bivalve molluscs.

VI. Prognosis for Host

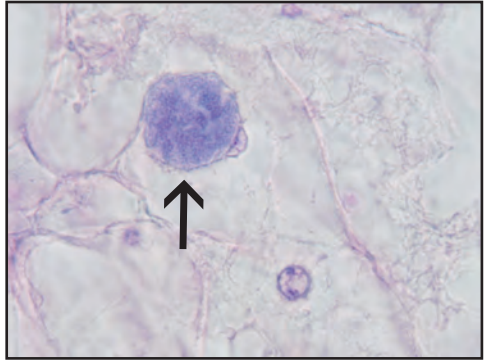
These organisms appear to be well tolerated with no harm to the host, despite sometimes heavy infections.

VII. Human Health Significance

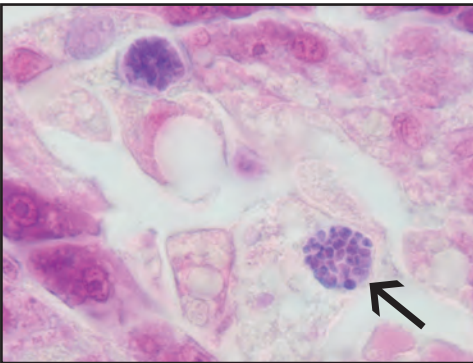
There are no known zoonotic human health concerns regarding infection of marine bivalve molluscs by these poikilothermic organisms which are different from similar organisms causing diseases in higher animals.



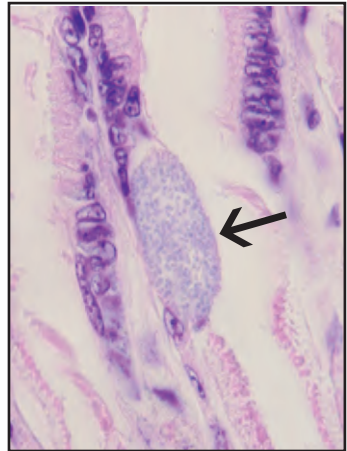
Histological section of RLO cytoplasmic inclusions (arrow) in digestive tubule epithelium of Pacific oyster



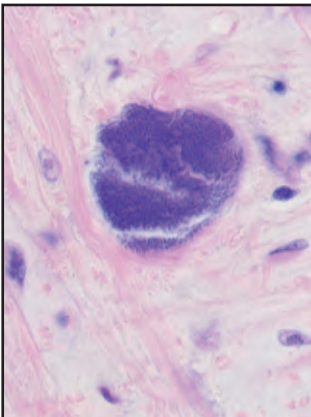
Histological section of RLO cytoplasmic inclusion (arrow) in a cell of the vesicular connective tissue of Pacific oyster



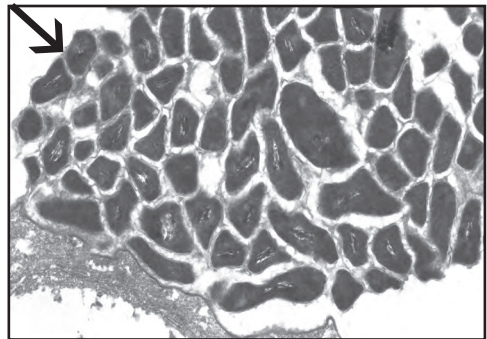
Histological sections of RLO cytoplasmic inclusions (arrow) in digestive tubule epithelium of basket cockle



Histological section of RLO cytoplasmic inclusion (arrow) in gill epithelium of basket cockle



RLO cytoplasmic inclusion in mantle muscle of littleneck clam



TEM of similar littleneck clam muscle inclusion showing rickettsia-like organisms (arrow)

Shell Fungus

I. Causative Agent

A fungal agent resembling *Penicillium* sp. was associated with abnormal brown/black conchiolin deposits on the inner surface of butter clams collected from Kodiak Island, Alaska. A different shell disease fungus, *Ostracoblabe implexa*, causes adductor muscle detachment and mortality characterized by inner shell conchiolin warts and severe thickening of the shell margin in oysters reported from Europe, India and on both Atlantic and Pacific coasts of Canada.

II. Host Species

The Alaskan shell fungus isolate has been detected in only one sample of butter clams from Kodiak Island collected in late 2005.

III. Clinical Signs

Clinical signs include brown to black semi-hard, flaky conchiolin deposits on the inside shell and around the mantle edges with no apparent mortality or unusual clam behavior.

IV. Transmission

The mode of transmission is unknown but likely horizontal via seawater.

V. Diagnosis

Abnormal brown to black conchiolin deposits are visible on the inside shell with associated septate fungal hyphae observed microscopically in wet mounts of the material. This fungus can be cultivated by inoculating the conchiolin material onto potato agar supplemented with 2% sodium chloride.

VI. Prognosis for Host

The prognosis for the host is un-

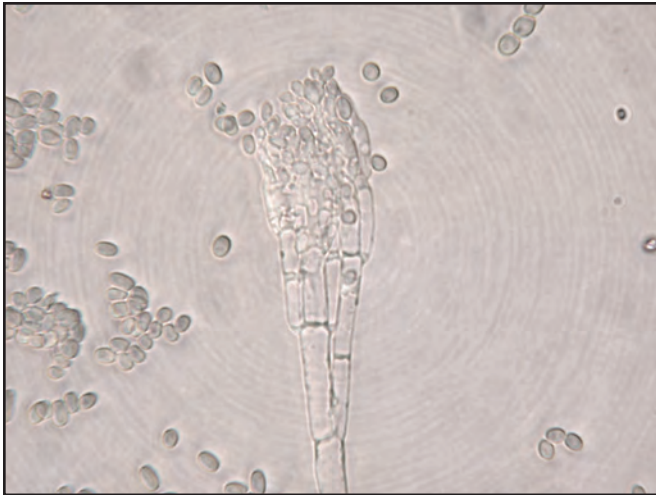
known but could lead to weakened shells and inability to close the valves properly if conchiolin deposits become too thick. The abnormal conchiolin deposition is a host response to wall-off or isolate an irritant.

VII. Human Health Significance

There are no known zoonotic human health concerns caused by this shell fungus.



Black conchiolin deposits (arrow) containing fungal hyphae on the inside shell surface of butter clams



Wet mount of conidiophore and typical conidia of *Penicillium*-like shell fungus from butter clams

Systemic Mycosis

I. Causative Agent and Disease

An unidentified marine fungus causes a systemic mycosis in basket cockles characterized by an intense inflammatory response with multiple granulomas containing necrotic cells and fungal hyphae. Infections have been discovered incidentally as well as associated with high mortality. There are no other known reports in the literature of a similar systemic fungus infection in adult bivalve molluscs.

II. Host Species

This fungus has been observed only in basket cockle populations from three locations in southeast Alaska during 1987 to 2005. The geographic distribution of the fungus in Alaska and whether other species of bivalves are susceptible are unknown.

III. Clinical Signs

The fungal infection may be grossly visible as external focal tissue discolorations with or without observed cockle mortality. Histological examination shows variable infiltration of host tissues by fungal hyphae that are contained within large granulomas.

IV. Transmission

The mode of transmission is unknown but is presumably horizontal via ambient seawater and/or the substrate where the cockles occur.

V. Diagnosis

Histological examination of hematoxylin and eosin stained material show large granulomas containing necrotic tissues and branching brown septate hyphae with basophilic conidia-like reproductive structures. Tissue sections of hyphae stain black (positive) by

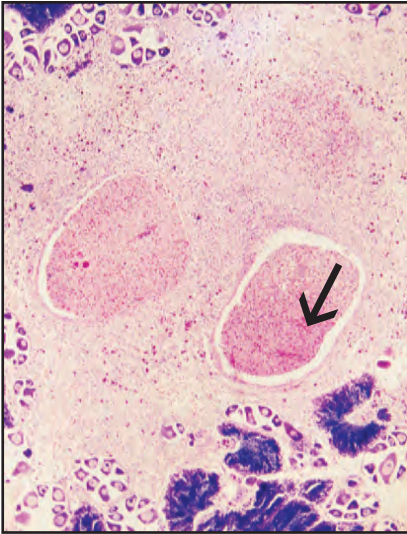
Grocott's method of methenamine-silver nitrate (GMS) for fungi. An opportunity has not occurred for further characterization of the fungus by attempted isolation on artificial media.

VI. Prognosis for Host

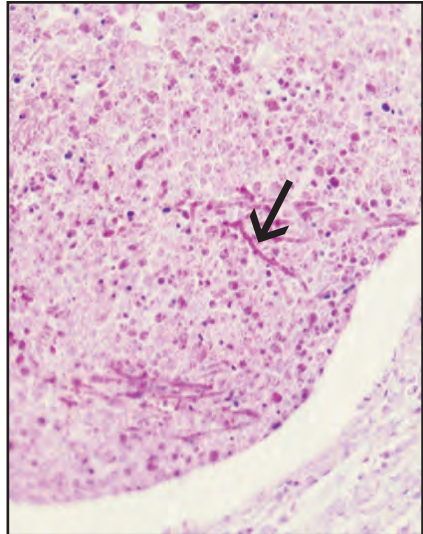
The fungal infection is highly invasive and likely responsible for the mortality of infected animals. The prevalence of this fungus in examined basket cockle populations has been low but its overall importance for causing enzootic disease is unknown.

VII. Human Health Significance

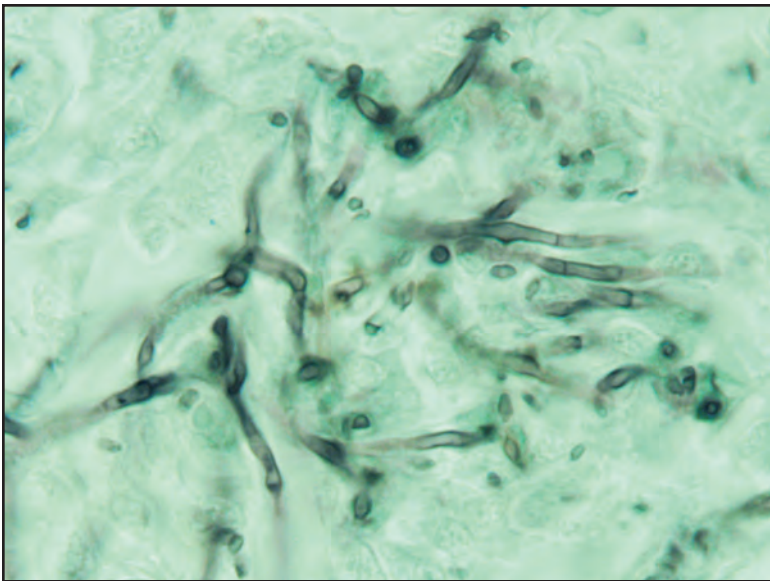
It is unlikely that this fungal infection in bivalve molluscs has any zoonotic significance for human health but definitive evidence is not available at this time.



Histological section of granuloma in connective tissue with two necrotic foci containing fungal hyphae (arrow)



Higher magnification of same necrotic focus with fungal hyphae (arrow)



GMS stain showing septate fungal hyphae (black)

Gill and Gut Ciliates

I. Causative Agent and Disease

The large thigmotrichid group of relatively non-pathogenic ciliated protozoa found in several species of bivalve molluscs occupy an existence between commensalism and parasitism. These ciliates include small unidentified thigmotrichs and *Sphenophrya* sp. found exclusively on the gills and palps and others found on the gills, palps and in the GI tract that include *Ancistrocoma* sp., *Stegotricha enterikos* and large unidentified ciliates.

II. Host Species

These protozoa are ubiquitous and commonly occur in Pacific, eastern and European flat oysters on the Atlantic, Pacific and Gulf coasts of North America but are also reported from several other bivalve species from Europe. In Alaska, these ciliates have been observed on the gills, palps and in the digestive tubules and intestines of Pacific oysters, blue mussels, basket cockles, rock and weathervane scallops and cultured juvenile littleneck clams.

III. Clinical Signs

There are no reported clinical signs of disease caused by these protozoa, although high intensities may cause localized tissues damage on histological examination and could be associated with physiological stress of the host. Occasionally, *Sphenophrya* sp. can produce xenomas (hypertrophied host cells containing one or many organisms) which do not appear to cause physical harm to bivalve hosts.

IV. Transmission

The mode of transmission is horizontal from host to host via ambient seawater.

V. Diagnosis

Small (4.5 X 7.0 μm to 6.5 X 10.0 μm) eosinophilic thigmotrich ciliates are commonly found on or slightly embedded within the gill or palps tissues by routine histological examination. Also occurring on the gill and palps tissues, *Sphenophrya* sp. is a larger basophilic crescent-shaped ciliate (maximum -15.0 X 23.0 μm) having a large elliptical macronucleus. The unidentified ciliates (possibly more than one species) are of variable size and found on the mantle, gills and within the GI tract. *Ancistrocoma* sp. and *Stegotricha* are spindle-shaped ciliates (50-70 μm in length) with large, granular, polymorphic nuclei. They are found mostly within the digestive tubule lumens (sometimes the intestine) by histological examination or by tissue squashes mounted in seawater where they can be observed as motile and attached forms. The morphology of these ciliates is more clearly observed by staining tissue smears with silver protein or iron hematoxylin. For the ciliates in the GI tract, the numbers and spacing of the somatic kineties (bands of cilia) are more clearly observed with these stains which are useful for determining species identification.

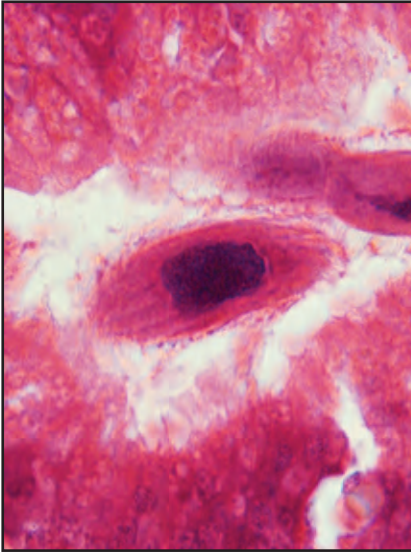
VI. Prognosis for Host

Often found at high prevalences but generally low intensities, these ciliates are relatively non-pathogenic. At high intensities they are capable of producing localized cell damage and excess mucus production. In gill infestations the laminar water flow essential for food particle transport across the epithelial surface may be disrupted. Because *Ancistrocoma* sp. is occasionally found on the gill tissues, the literature has suggested that those reported internally in both Pacific

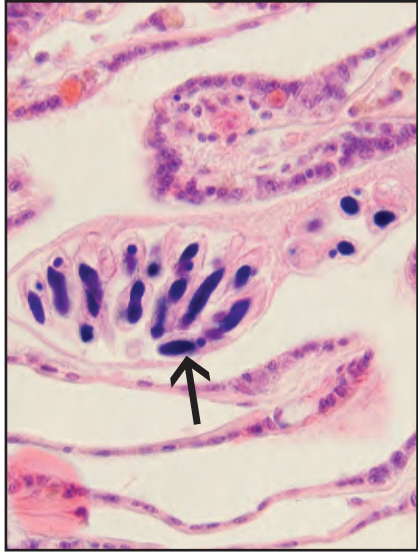
and eastern oysters may be normal gill parasites which invade the GI tract during abnormal conditions of physiological stress. This may also be true for some of the unidentified ciliates.

VII. Human Health Significance

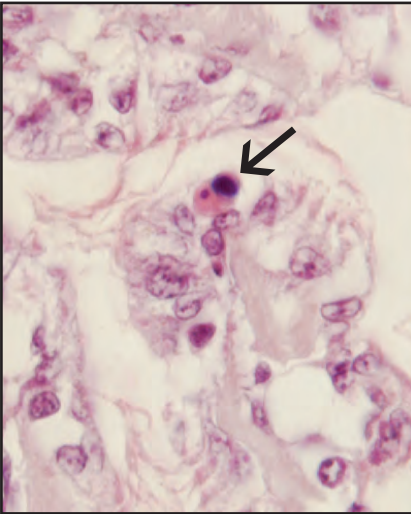
There are no zoonotic human health concerns regarding the presence of these ciliated protozoa on or within bivalve mollusc tissues.



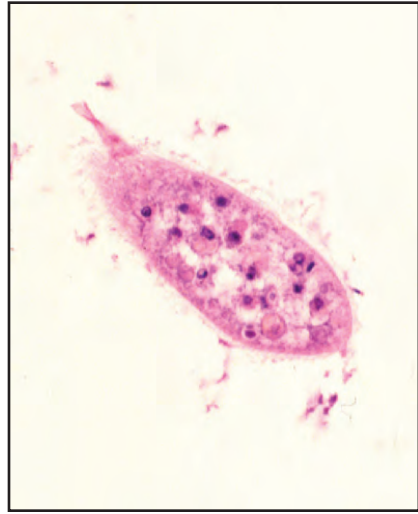
Histological section of *Ancistrocoma*-like ciliate in the digestive tubule of Pacific oyster



Xenoma of gill epithelial cell in blue mussel formed by *Sphenophrya* sp. (arrow)



Histological section of small thigmotrich ciliate (arrow) on gill epithelium of Pacific oyster



Histological section of large unidentified ciliate on gill tissues of native littleneck clam containing consumed host cells

Haplosporidium sp.

I. Causative Agent and Disease

Protozoa of the genus *Haplosporidium* sp. belong to the phylum Haplosporidia, class Haplosporea within the order Haplosporida in the family Haplosporidiidae. These are obligate parasites, some of which are extremely important pathogens of oysters. One such species, *H. nelsoni*, was responsible for MSX (multinucleate sphere unknown) later known as Delaware Bay Disease that caused the demise of the eastern oyster in higher salinity (>15 but < 25 ppt) areas of Delaware and Chesapeake Bays from 1957 through 1960. Systemic plasmodial life stages of the parasite can cause extensive necrosis of all tissues resulting in mass mortality. Occurring at about the same time another species, *H. costalis* or SSO (Seaside Organism), caused serious mortality in eastern oysters rearing in higher salinity waters (> 25 ppt) on the seaside coasts of Virginia and Maryland.

II. Host Species

Haplosporidium nelsoni has been reported in eastern oysters on the Atlantic coast of North America as far north as Bras d'Or Lakes, Nova Scotia, Canada south to Florida. A morphologically similar *Haplosporidium* sp. in Pacific (Japanese) oysters in Korea and Japan and on the Pacific coast of North America was determined by DNA sequence analysis to be *H. nelsoni* apparently introduced to the Pacific Northwest from Asia. The parasite was then introduced to the Atlantic coast with west coast Pacific oysters sometime before the epizootics occurred in Delaware Bay. *Haplosporidium armoricana* has been reported in the European flat oyster

in France, Britany and the Netherlands. Other *Haplosporidium* species have also been reported in California sea mussels (*H. tumefacientis*) from California, blue mussels (*Haplosporidium* sp.) from Maine, gaper clams and native oysters (*Haplosporidium* sp.) from Oregon, carpet-shell and Manila calms (*H. tapetis*) from France, Spain and Portugal. Unidentified *Haplosporidium* sp. were also found in cockles from France, black-footed abalone in New Zealand and in toredo ship worms from New Jersey, U.S.A. In Alaska, only one case of a bivalve haplosporidian is on record regarding an unidentified *Haplosporidium* sp. producing plasmodia in the gill connective tissues of a single razor clam collected from the southcentral area in 1991. No disease or mortality were associated with this finding.

III. Clinical Signs

Non-specific clinical signs of haplosporidiosis parasitism are more severe in oysters and can include mantle recession, gaping valves, watery emaciated tissues, pale digestive gland and rarely yellow-brown conchiolin deposits forming on the inner shell. Dissemination of plasmodial stages of the parasite throughout all tissues with associated host cell inflammatory infiltration and cell necrosis are evident by histological examination.

IV. Transmission

Haplosporidium sp. produce operculate spores which are not directly infectious but likely require, a yet unknown, intermediate host. The complete life cycle and infective stage are unknown but once in the bivalve host a modified type of shizogony gives rise to multinucleated

plasmodia. These plasmodia develop into sporonts that become sporocysts enclosing several spores that are released into the environment from moribund or dead bivalve hosts.

V. Diagnosis

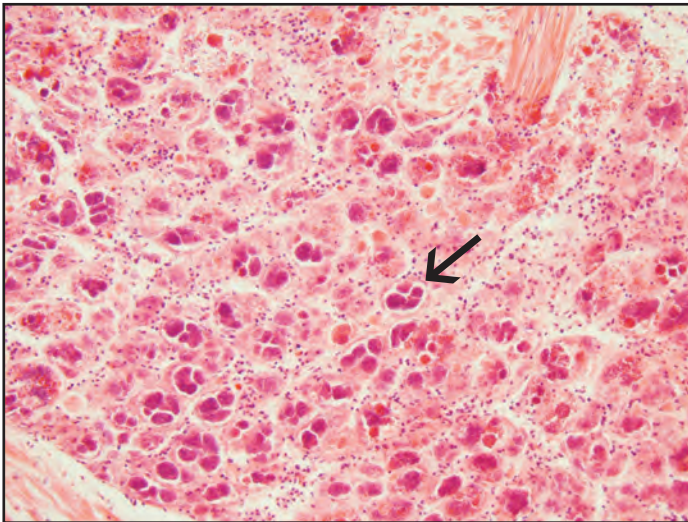
Preliminary diagnosis for all *Haplosporidium* sp. is based on histological examination showing the typical plasmodia varying in size from 5 to 100 µm found in various host tissues. The larger spores of *H. nelsoni* (5.4 X 7.5 µm) are rarely found in adult oysters but are frequent in juveniles occurring only in the digestive gland epithelium. Smaller spores (3.3 X 4.3 µm) of *H. costalis* occur throughout the connective tissues but not in the digestive gland epithelium. Spores of both species (probably other haplosporidia as well) are red (acid-fast) using the Ziehl-Neelsen stain. Confirmatory tests using PCR and DNA probes are available for *H. nelsoni* and possibly other species of haplosporidia.

VI. Prognosis for Host

Various species of *Haplosporidium* sp. have caused significant bivalve mortality and are serious pathogens that should not be introduced into new areas via shellfish transports. Salinity and sea-water temperature are important limiting factors for parasite development and disease that have been used to reduce oyster losses due to *H. nelsoni* and *H. costalis*. This strategy may also be useful to control other haplosporidia. Haplosporidiosis in Pacific oysters has not been associated with mortality of that species. On the east coast selectively bred eastern oysters that are genetically resistant to *H. nelsoni* have been deployed commercially on a limited basis.

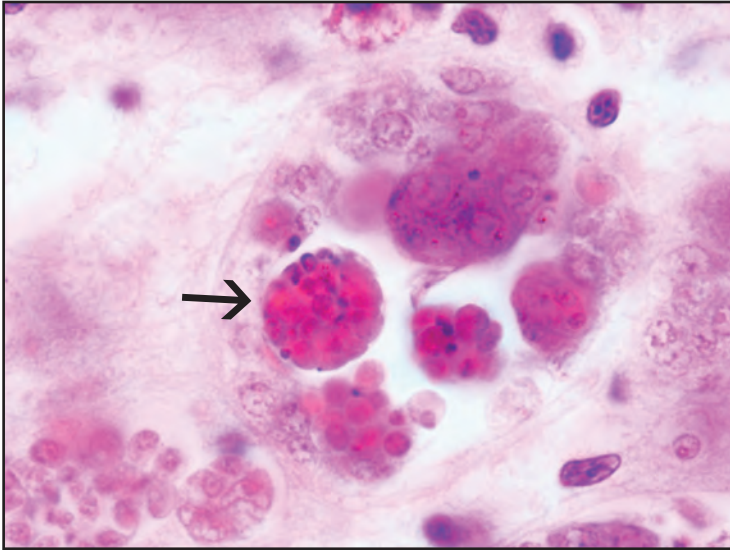
VII. Human Health Significance

There are no zoonotic human health concerns associated with haplosporidian parasitism of bivalve mollusc tissues.

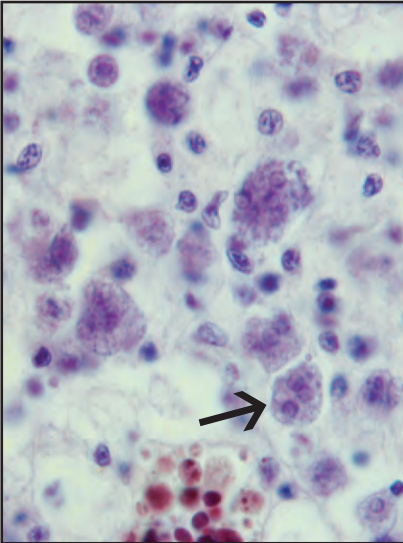


Haplosporidia-like sporonts (arrow) in the gill connective tissues of Alaskan razor clam

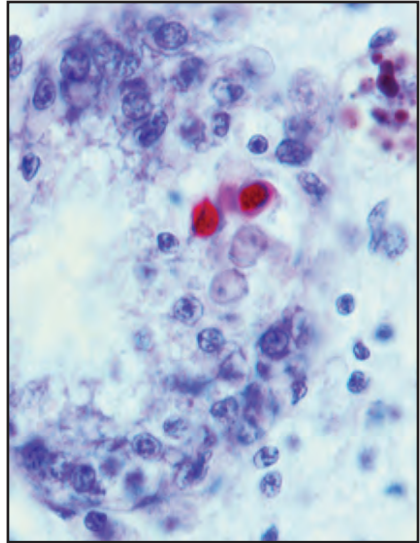
Haplosporidium sp.



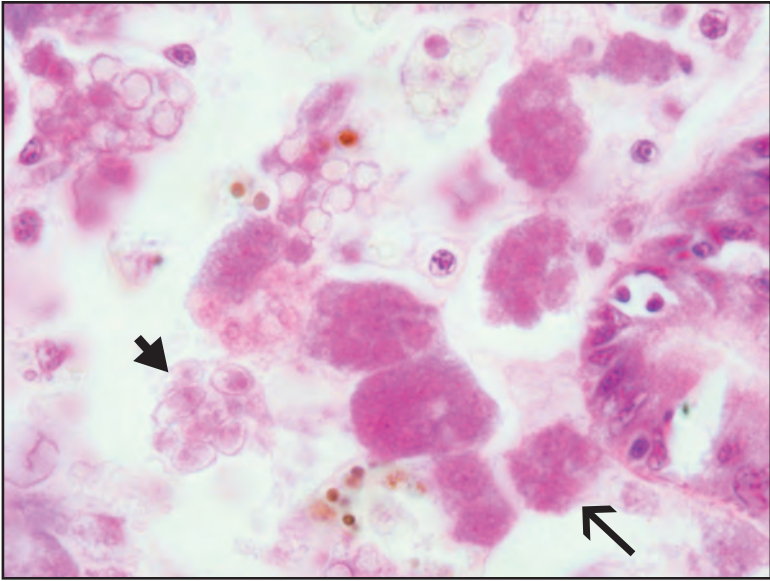
Histological section showing various stages of haplosporidia-like sporonts (arrow) and spore development in the gill connective tissues of Alaskan razor clam



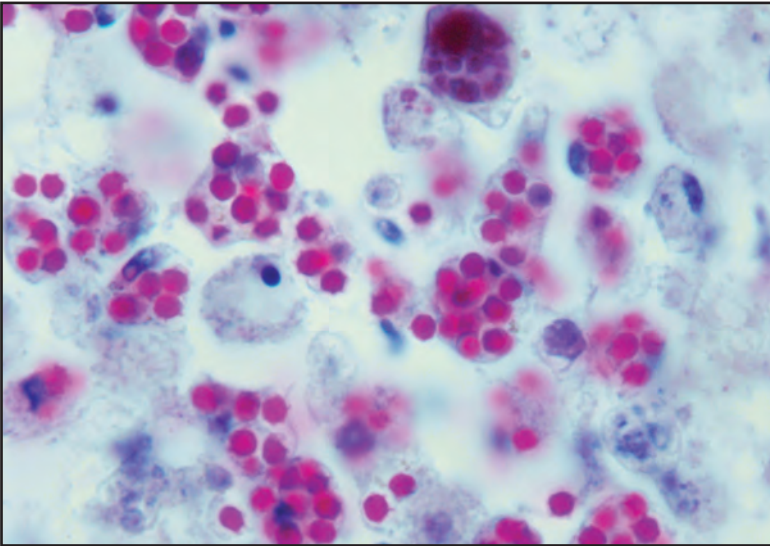
Histological section of eastern oyster with MSX plasmodia (arrow) in connective tissues



Histological section of eastern oyster with MSX acid-fast spores (red) within the digestive tubule epithelium



Histological section of eastern oyster with SSO plasmodia (arrow) and spores (arrow-head) in connective tissues



Histological section of eastern oyster exhibiting SSO acid-fast spores (red) in connective tissues

Hexamita

I. Causative Agent and Disease

Hexamita (nelsoni and inflata)

is a zooflagellate protozoan that is a free-living saprophyte occurring in the vicinity of oyster beds. It can become a facultative parasite when environmental conditions are unfavorable or may become a secondary pathogen of oysters dying from other diseases. *Hexamita* is commonly found in low numbers within the intestinal tract of oysters with no associated pathology.

II. Host Species

Hexamita can be found associated with several different species of oysters worldwide. It has been associated with mortality of the native oyster in winter during cold seawater temperatures in Puget Sound, Washington and mortality of the European flat oyster in recirculating seawater pits (Pit Disease) in the Netherlands. *Hexamita* sp. has been detected once in southeast Alaska during 1987 as a secondary pathogen associated with opportunistic bacteria contributing to summer mortality in 18 month-old Pacific oysters stressed by high seawater temperatures and rapid gonadal development.

III. Clinical Signs

Diseased oysters have no specific gross clinical signs but hemolymph smears may contain large numbers of the flagellate while systemic infestation by the parasite is evident in all tissues by histological examination.

IV. Transmission

The mode of transmission is horizontal since *Hexamita* sp. occurs as a saprophyte in ambient seawater and as part of the normal gut flora of healthy oysters.

V. Diagnosis

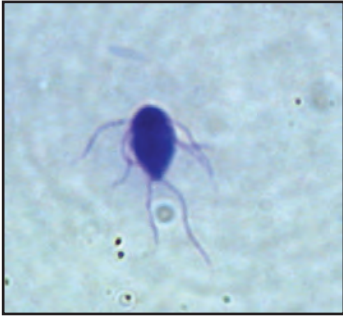Hexamita, as observed in hemolymph smears or tissue squashes, is very motile and pyriform in shape, about 14-17 μm long by 7-10 μm wide and has 6 anterior and 2 posterior flagella. Mixed populations of bacterial rods may also be present in the hemolymph of moribund or dead oysters. Histological examination demonstrates the protozoan in gut lumens of healthy animals. In diseased animals the organism is present on mantle and gill surfaces and throughout all tissues as are various bacteria and tissue necrosis. *Hexamita* can be cultured in artificial media and in filtered seawater containing antibiotics. Identification of the organism to species requires silver impregnation stains to reveal distinguishing morphological characteristics.

VI. Prognosis for Host

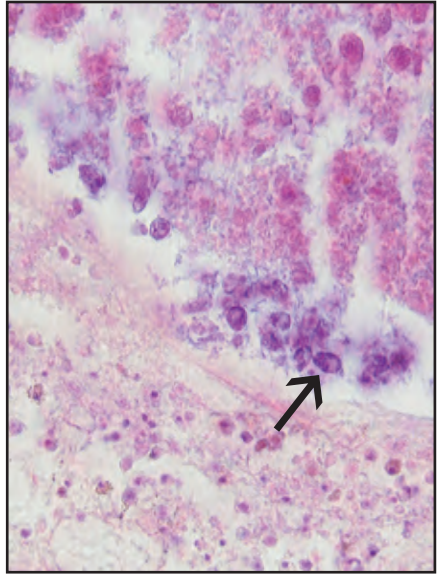
Hexamita may be found at low intensities and generally does not invade the tissues of healthy oysters except when poor or extreme environmental conditions (high temperatures, low temperatures $< 6^{\circ}\text{C}$, poor water quality) cause physiological stress. In such cases, overwhelming systemic disease can occur with reported mortality greater than 50% in Alaskan Pacific oysters and up to 75% in native oysters from Puget Sound, Washington.

VII. Human Health Significance

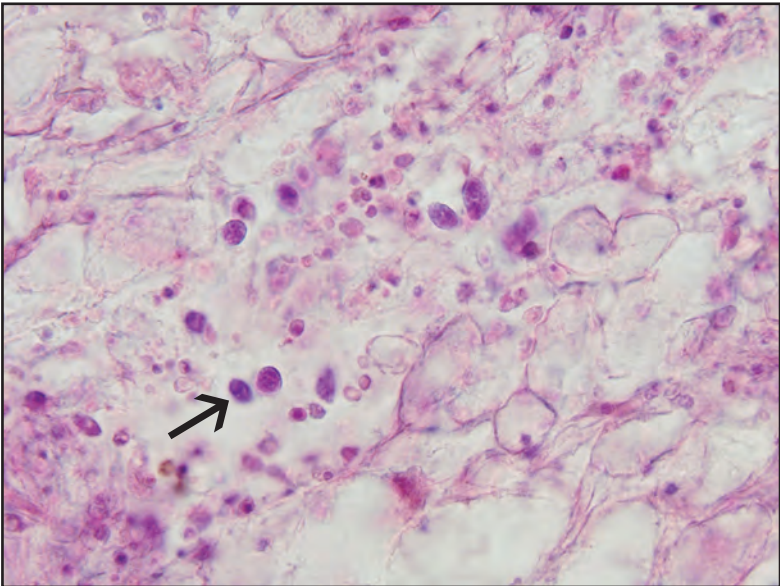
There are no zoonotic human health concerns regarding the presence of *Hexamita* in oyster tissues.



Hexamita sp. in a Giemsa stained smear



Histological section of *Hexamita* sp. (arrow) within the intestine of Pacific oyster associated with a bacterial infection



Histological section of *Hexamita* sp. (arrow) within the connective tissues of Pacific oyster

Ichthyobodo-Like Protozoan

I. Causative Agent and Disease

Protozoa of the genus *Ichthyobodo* belong to the family Bodonidae, order Kinetoplastida of the class Kinetoplastida within the flagellate phylum of Mastigophora. *Ichthyobodo necator* (synonym *pyriformis*) is a serious obligate ectoparasite of fishes in both the freshwater and marine environments but similar protozoa have not been described occurring on the surface of bivalve molluscs. Therefore, the disease potential of this ectoparasite in bivalves is unknown.

II. Host Species

There are no reports of a similar appearing parasite occurring on the surface tissues of bivalve molluscs, therefore the potential host species are unknown. In Alaska, this parasite has been observed attached to mantle epithelium from 8 of 15 adult weathervane scallops collected in Yakutat, Alaska during December 1990. No mortality or clinical disease were associated with this finding.

III. Clinical Signs

No gross clinical signs are evident but the parasite can be observed attached to mantle epithelium by histological examination.

IV. Transmission

The route of transmission is unknown but presumed to be horizontal via seawater by a motile flagellated non-feeding form as described for this group of organisms. The parasite alternates between a free swimming and a non-motile feeding stage that attaches to a host epithelial cell. Replication of the protozoan in fish is by asexual longitudinal fission where one cell produces two motile daughter cells, each with

two flagella, that parasitize the same or a different host. Motile forms attach by means of a flat disc with two small microtubules extending into the host cell, but retain flagella.

V. Diagnosis

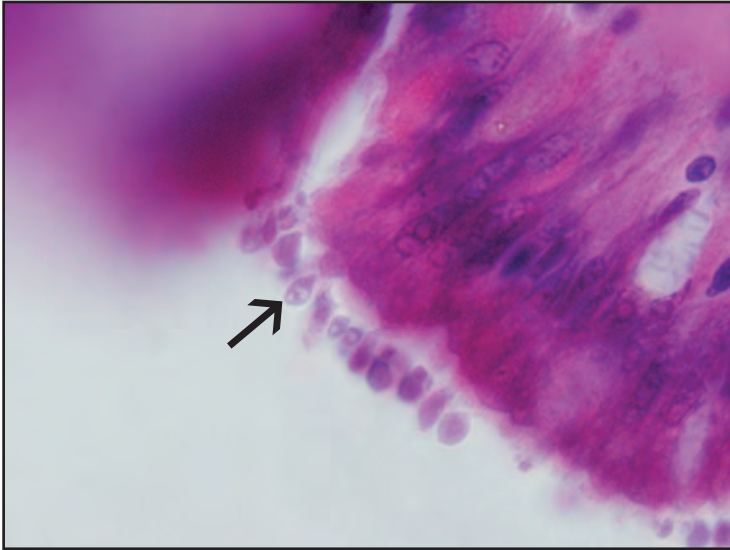
Diagnosis is by histological examination showing very small pyriform-shaped (5-10 μm) feeding forms of the parasite attached to epithelial cells of the mantle surface.

VI. Prognosis for Host

The prognosis for the host is unknown but in this case the parasite is presumed to be relatively harmless based on the lack of significant tissue pathology. However, it is plausible that high parasite intensities on juvenile animals could result in significant pathological changes.

VII. Human Health Significance

There are no zoonotic human health concerns regarding the occurrence of this parasite on external tissues of bivalve molluscs.



Histological section of *Ichthyobodo*-like protozoa (arrow) attached to the mantle epithelium of weathervane scallop

Nematopsis and Other Gregarines

I. Causative Agent and Disease

Oocysts of several different species of *Nematopsis* gregarines of the family Porosporidae, subclass Gregarina, class Sporozoa infest various tissues of many species of bivalve molluscs causing no significant harm to the hosts. Encysting trophont stages of other gregarine-like organisms observed primarily in oysters infest the epithelial mucosa of the gut, again causing little tissue damage. A third type of systemic gregarine-like trophozoite stage has been reported in bivalves infesting all tissues causing localized hemocyte accumulations and phagocytosis, but otherwise is not pathogenic.

II. Host Species

Gregarine parasites are cosmopolitan in the oceans of the world while individual species may have more confined distributions. Oocysts of *Nematopsis* species commonly reported from eastern and Pacific oysters belong to *N. ostrearum* and *N. prytherchi* that also infest other scallops and clams and use at least 5 xanthid species of crab as final hosts. Oocysts of *Nematopsis duorari* infest several marine molluscs and the parasite uses the pink shrimp as a definitive host. Other unidentified gregarine-like encysting trophont stages in the gut mucosa have been reported from the eastern oyster on the Atlantic coast of the U.S. and in Pacific oysters and Manila clams in the Pacific Northwest while the systemic gregarine-like trophozoite has been reported from Washington State and British Columbia, Canada in Pacific oysters and Manila clams. In Alaska, oocysts of *Nematopsis* sp. have not been observed in Pacific oysters but have been found in the gills and connective tissues of littleneck clams, basket cockles, blue mussels,

rock scallops and weathervane scallops.

Localized gregarine-like trophont stages in the gut and gills have been observed in Alaskan Pacific oysters, blue mussels and rock scallops while systemically distributed gregarine-like trophozoites have been found in Pacific oysters, blue mussels and littleneck clams.

III. Clinical Signs

These gregarine organisms are found incidentally in apparently healthy bivalve molluscs showing no outward clinical signs of disease. Oocysts and vegetative stages within bivalve tissues are discovered by routine histological examination.

IV. Transmission

The life cycle of gregarines requires two hosts, a marine mollusc as the intermediate host and a marine arthropod, generally a crustacean, as the final host. Trophozoites in the gut of a crustacean host give rise to gametocysts and gamete formation resulting in sporulation and the production of gymnosporos. Gymnosporos, released from ruptured gametocysts, are eliminated with feces and eventually come into contact with a suitable mollusc. Gymnosporos cause a host cellular response and are engulfed by phagocytes that pass back into the mollusc host through the mantle epithelium. The engulfed gymnosporos gives rise to sporozoites which, in the genus *Nematopsis*, form resistant oocysts each containing one sporozoite. Sporozoites in oocysts are eaten when the bivalve host is consumed by the crustacean final host and give rise to trophozoites which completes the life cycle.

V. Diagnosis

Wet mounts of infected tissues

reveal typical oocysts while histological examination is less sensitive but allows detection of both oocysts and vegetative troph stages within the bivalve tissues. *Nematopsis* oocysts are characterized by a thick hyaline capsule enclosing a densely basophilic worm-like sporozoite coiled within. Oocysts in oysters range in size from 14-19 μm X 10-16 μm and are found most commonly in the gill connective tissues. The term “gregarine-like” is used for organisms resembling the vegetative stages of gregarines for

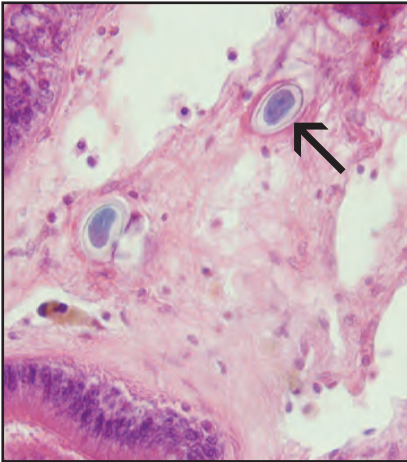
which spores have not been found to allow definitive identification.

VI. Prognosis for Host

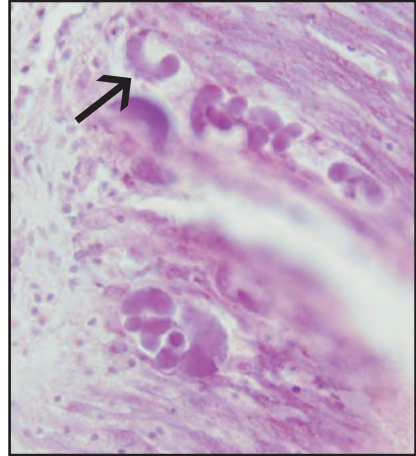
Gregarine parasites do not appear to negatively impact their intermediate bivalve mollusc hosts.

VII. Human Health Significance

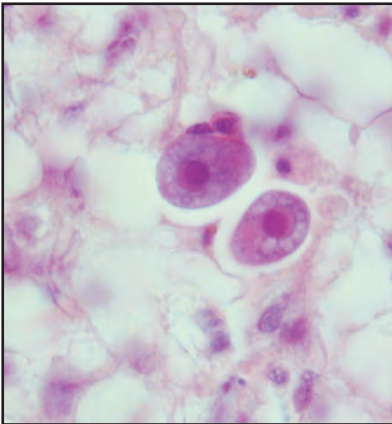
There are no zoonotic human health concerns regarding the occurrence of gregarine parasites in bivalve mollusc tissues.



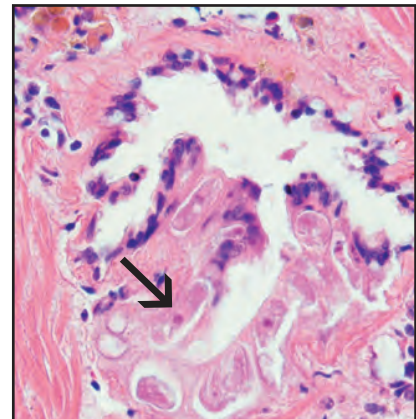
Histological section of oocysts (arrow) of *Nematopsis* sp. in the connective tissues of weathervane scallop



Histological section of gregarine-like trophont stages (arrow) in the intestinal epithelium of Pacific oyster



Histological section of gregarine trophont stages in the connective tissue of Pacific oyster



Histological section of gregarine trophont stages (arrow) within the water tubules of the gill in basket cockle

Steinhausia sp. and Other Unidentified Microsporidia

I. Causative Agent and Disease

Microsporidia is a protozoan order within the class Microsporea within the phylum Microspora. However, there is controversial genetic evidence for a closer affinity to the kingdom of Fungi rather than Protozoa. A small number of Microspora parasitize marine bivalves. They are intracellular parasites producing smaller microspores (3 to 6 μm) and complete their life cycles in a single host cell, generally with no alternate hosts. Identified microsporidian species in bivalve molluscs include *Steinhausia ovicola* and *S. mytilovum* that are parasites of ova in female bivalves and cause no significant harm. Several other unidentified microsporidia have been described in ova, connective tissues and the digestive gland but also causing no significant disease.

II. Host Species

Steinhausia has been described parasitizing wild and cultured bivalves in the ova of the European flat oyster (*S. ovicola*), oocytes of blue and gallo mussels (*S. mytilovum*) and cockles (*Steinhausia* sp.) in France, in *Mytilus* sp. (*S. mytilovum*) from Korea and Japan, the blue mussel (*S. mytilovum*) from the Atlantic coast and in the gallo mussel (*S. mytilovum*) on the Pacific coast of the U.S., Italy, Spain and Greece. Other unidentified microsporidia have been reported from: the ova of Australian blacklipped oysters; connective tissues surrounding the gut of New Zealand dredge oysters; connective tissues of the digestive gland in queen scallops in the United Kingdom; the digestive gland of cockles in France; and in the U.S. from ova of *Macoma* clams in Maryland and from ova of Pacific oysters in California. In Alaska, *Steinhausia*-like

sporonts have been observed in the ova of native littleneck clams and spores of unidentified microsporidia have occurred in the nervous tissue, mantle connective tissue and foot muscle of littleneck clams and basket cockles.

III. Clinical Signs

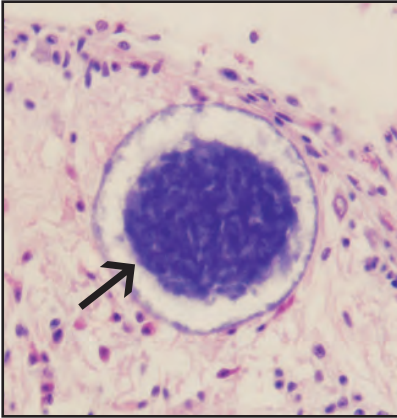
Parasitized bivalves appear healthy with no clinical signs of disease or mortality. The microsporidia in ova and various other tissues are incidental findings during routine histological examination.

IV. Transmission

Transmission is horizontal when spores released from ruptured host cells are ingested by a suitable host. In the intestine of the new host each spore releases a hollow polar tube attaching the spore to a mucosal epithelial cell through which the internal amoeboid sporoplasm passes into the host cell. The sporoplasm may replicate in the intestinal cell or may be injected into a host phagocyte where it travels to other target tissues. In addition to transmission via the alimentary tract, reports have hypothesized that *Steinhausia* sp. may also be vertically transmitted to progeny when lightly parasitized ova develop normally. Replication of *Steinhausia* sp. has also been reported in oocyte nuclei of some bivalve species. Once in the target host cell the parasite undergoes further replication and development involving merogony producing plasmodia and meronts followed by sporogony producing sporonts that contain sporoblasts that mature into spores. The entire process is complex and may have other intermediate stages depending on the species of microsporidia.

V. Diagnosis

Histological examination may detect the presence of microspores within various bivalve tissues or within sporocysts in the cytoplasm of maturing or well developed ova. Multiple immature sporonts (sporocysts) may be present with no visible spores. Genus and species identification by histology alone is generally not possible and would require closer morphological examination by transmission electron microscopy.



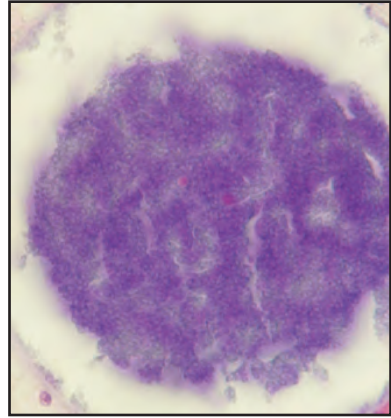
Histological section of microspores (arrow) of an unidentified microsporidian in the pallial nerve of basket cockle

VI. Prognosis for Host

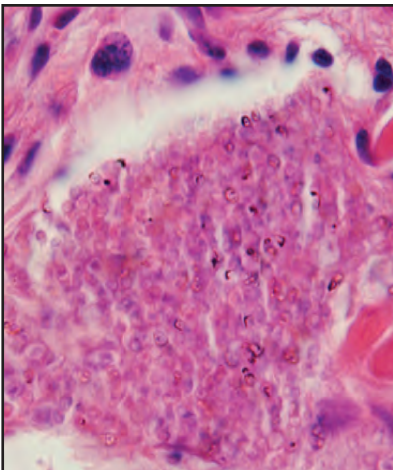
Microsporidian parasites do not appear to cause significant harm to their bivalve mollusc hosts.

VII. Human Health Significance

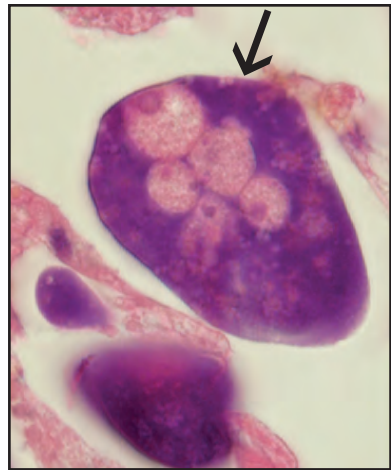
There are no zoonotic human health concerns regarding the presence of microsporidian parasites within the tissues of bivalve molluscs.



Higher magnification of microspores at left



Microspores of an unidentified microsporidian in the foot muscle of basket cockle



Sporonts of a *Steinhausia*-like microsporidian in an oocyte (arrow) of native littleneck clam

Trichodinid Ciliates

I. Causative Agent and Disease

Peritrichous ciliates of the genera *Trichodina*, *Urceolaria* and *Leiotrocha* are common parasites of several species of marine molluscs. Under normal circumstances these ectoparasites are regarded as more commensalistic and harmless but when present in large numbers they may cause disease. *Trichodina* sp. is the most common genus and has been associated with recurrent large scale mortality of cockles in Germany and possibly oysters in France (a virus may also have been present) during warmer summer/fall seawater temperatures. The mortality described in parasitized bivalves was likely due to overwhelming erosion of gill tissues that disrupts normal respiratory function followed by possible microbial secondary infection.

II. Host Species

Trichodina sp. has been reported from various species of clams, cockles, scallops and oysters from Europe, the Atlantic coast of the United States and the Pacific rim. In Alaska, unidentified trichodinid ciliates have been found on the gills, palps and mantle tissues of Pacific oysters, basket cockles, rock and weathervane scallops.

III. Clinical Signs

Trichodinids observed in Alaska were found incidentally during routine histological examination of apparently normal bivalve molluscs with no associated mortality or other clinical signs of disease. Cockle and oyster mortalities in Europe and France that were associated with *Trichodina* infestations occurred mostly in juvenile or otherwise younger animals. Clinical signs included emaciated soft tissues, grey-colored digestive

glands, eroded and deformed gills with large numbers of the ciliates present.

IV. Transmission

Transmission of trichodinid parasites is horizontal via ambient seawater. Older less susceptible adult bivalve molluscs are reservoirs for the parasite which cannot survive long outside a host.

V. Diagnosis

Tissue wet mounts of trichodinid ciliates demonstrate a saucer or disc-shaped motile organism of variable diameter (33-103 μm) that often rotates in place. Visible are a ventral ring of denticles (teeth) with a ciliary girdle and a dorsal adoral ciliary ring. Histological examination of gills, palps and mantle demonstrates an eosinophilic helmet-shaped ciliate with a large horseshoe-shaped nucleus, the ends of which appear as two "eyes" in most sections. Specific identification of genus and species is accomplished by silver impregnation staining of smears to reveal the arrangement and number of denticles as well as other features of parasite morphology.

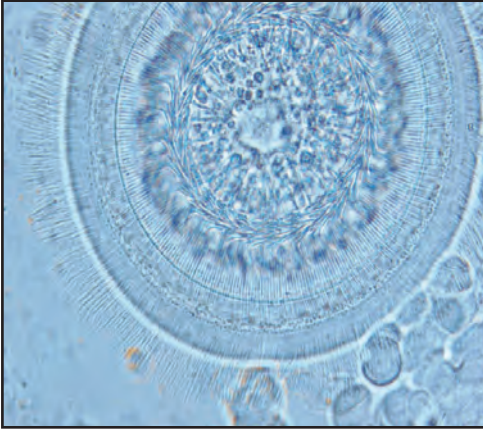
VI. Prognosis for Host

Trichodinid parasites usually occur in low numbers as harmless commensals feeding on bacteria, surface detritus and surface tissue cells of the host. Significant tissue damage is avoided by the regenerative capacity of a healthy host and the natural equilibrium between rates of parasite multiplication and accidental parasite expulsion with the normal flow of seawater maintained by the host in the pallial cavity. Environmental or physiological stress of the host reduces ciliary activity and the pumping action of the gills. This reduces the frequency

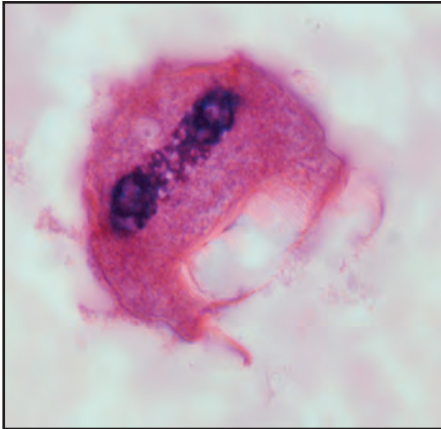
of parasite expulsion leading to increases in parasite abundance, tissue damage and excessive mucus production followed by possible death of the host. Older adult bivalves are reservoirs of the parasite that can infest the more susceptible juvenile molluscs.

VII. Human Health Significance

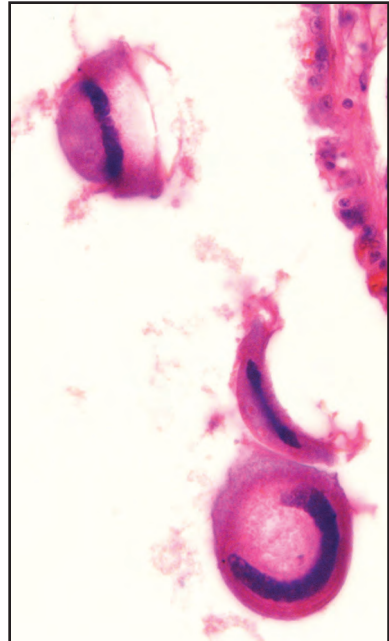
There are no zoonotic human health concerns with the occurrence of trichodinid parasites in bivalve molluscs.



Wet mount of *Trichodina* protozoan showing cilia and denticles



Histological section of a trichodinid ciliate on the mantle surface of Pacific oyster



Histological section of trichodinid ciliates on the gill surface of Pacific oyster

Unidentified Kidney Coccidia and Others

I. Causative Agent and Disease

Coccidiasina is a subclass within the class Conoidasida in the phylum Apicomplexa. These protozoa are intracellular parasites of vertebrates as well as invertebrates. Some members of two suborders, Adeleorina and Eimeriorina, parasitize bivalve molluscs in the kidneys (*Pseudoklossia glomerata*, *P. pectinis*, *P. pelseneeri*, *Klossia tellinae*), germ cells of the ovarian tubules (*Merocystis tellinovum*), developing ova (unidentified coccidia), connective tissues (unidentified coccidian sporocysts) and sometimes visceral ganglia (*P. glomerata*). Coccidia of bivalve molluscs are of two types: those that complete part of their life cycle in bivalves and presumably require an alternate host because certain developmental stages have not been observed; and those organisms that complete their entire life cycle within their bivalve hosts where all developmental stages have been described. Depending on the species of bivalve host, tissue degeneration and necrosis from the intracellular development of these parasites ranges from minor in developing ova to severe kidney damage or parasitic castration of females when infecting germ cells. Severe kidney tubule infestation of an unidentified coccidian in Canadian bay scallops reportedly resulted in systemic dissemination of the parasite into various other tissues. No mortality directly related to coccidian parasitism in bivalves has been documented in feral populations but has been reported in scallops during at least one situation of recirculating hatchery culture.

II. Host Species

Coccidia have been described infecting *Tapes* and *Tellina* clams in the

Mediterranean Sea, England and Scotland, *Pecten* scallops and the European flat oyster in France, cockles in Spain, blacklip oysters in Australia and in blue mussels, bay scallops and the eastern oyster on the Atlantic coast of North America and on the Pacific coast in the native littleneck clam in Washington State and in blue mussels, native littleneck and Japanese littleneck (Manila) clams in British Columbia, Canada. In Alaska, an unidentified kidney coccidian (possibly multiple species) has been found in 12-33% of examined blue mussels, basket cockles and native littleneck clams. Also, varying prevalences of littleneck clams from all Alaskan locations (total prevalence ~ 62%) have been parasitized by a sporocyst stage of another unidentified coccidian disseminated throughout all connective tissues. A light intensity of similar sporocysts have also been found in the connective tissues surrounding the gut of a single butter clam.

III. Clinical Signs

The kidney coccidian in native littleneck clams from Washington State reportedly causes behavioral modification such that live parasitized clams are found on the surface of the sand substrate ("kick-outs") rather than buried underneath. Otherwise there are no other gross clinical signs of disease or mortality in the other reported infestations. Routine histological examination detects these coccidia within their respective target host tissues with varying degrees of cell damage or host response ranging from none to significant in the case of certain kidney coccidia.

IV. Transmission

Transmission of these coccidia is likely horizontal via ambient seawater

but many may require at least one alternate host to complete their life cycles. The typical life cycle producing the developmental stages of coccidia can be divided into three phases: asexual merogony (schizogony) where multiplication occurs inside the specific host target cells producing trophozoites giving rise to schizonts containing merozoites that infect other cells to continue merogony or to begin gamogony; sexual gamogony (anisogony) where merozoites, upon entering host cells, transform into gamonts of macrogametes (female) and biflagellated microgametes (male) that join to form a zygote or oocyst; and asexual sporogony where oocyst cytoplasm divides to contain sporoblasts that develop into sporocysts each containing sporozoites that, when liberated from the oocyst, infect cells to start the entire cycle anew. For most coccidia in bivalve molluscs gamogony and sporogony occur in the bivalve host with merogony presumably occurring in other hosts that have not been identified. The few remaining reported coccidia apparently complete all developmental phases in the bivalve host.

V. *Diagnosis*

Large mature macrogamonts may be observed in squash preparations of kidney tissues while all intracellular developmental stages may be observed by histological examination. The kidney coccidian of the Alaskan littleneck clam appears identical to one reported in the same clam species in Washington State and is likely an undescribed species based on: the apparent completion of its entire life cycle in the clam; the production of a thick-walled spore in addition to a thin-walled oocyst; and the presence of tetrazoic (4 sporozoites) sporocysts instead of dizoic sporocysts. Large sporocysts of another unidentified coccidian disseminated throughout the

connective tissues of Alaskan littleneck clams typically contain elongate sporozoites (28 μm by 4 μm). Generic and species identification of coccidia are based primarily on the structure of oocysts and sporocysts as well as the number of sporocysts contained by the oocyst.

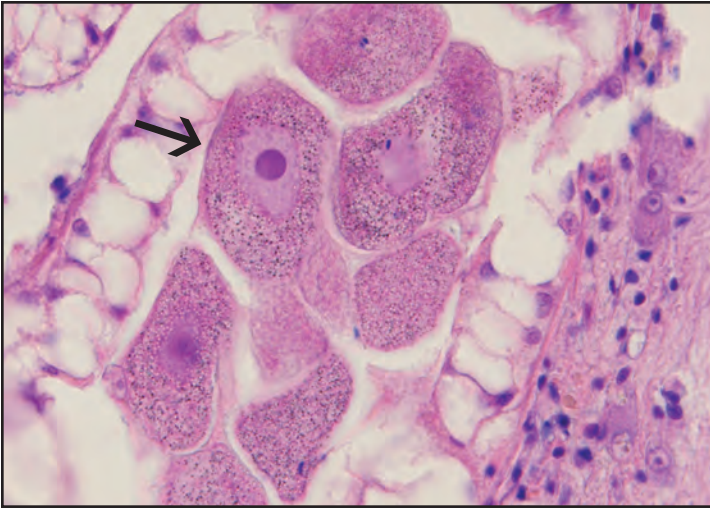
VI. *Prognosis for Host*

The effects of coccidia on host bivalve molluscs is variable ranging from no effect to significant kidney necrosis and parasitic castration in females. In Alaska, moderate host inflammatory infiltration with minor kidney necrosis caused by infestation has been observed in two basket cockles. However, generally these parasites have appeared harmless in wild as well as cultured bivalve species.

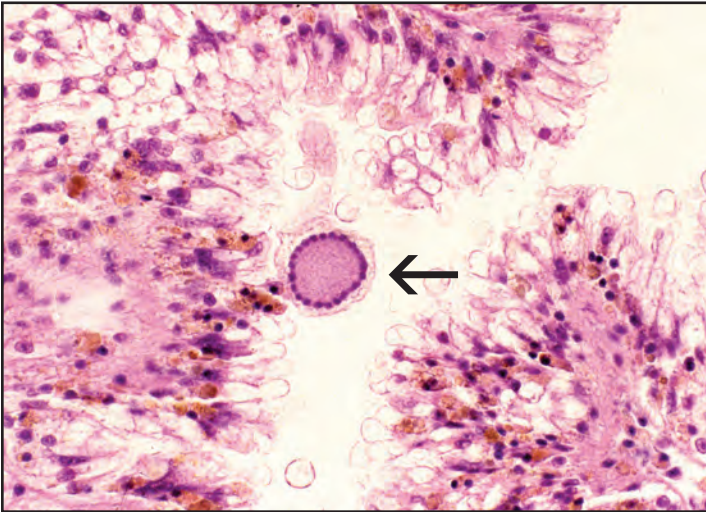
VII. *Human Health Significance*

There are no zoonotic human health concerns regarding these coccidian parasites in bivalve mollusc tissues.

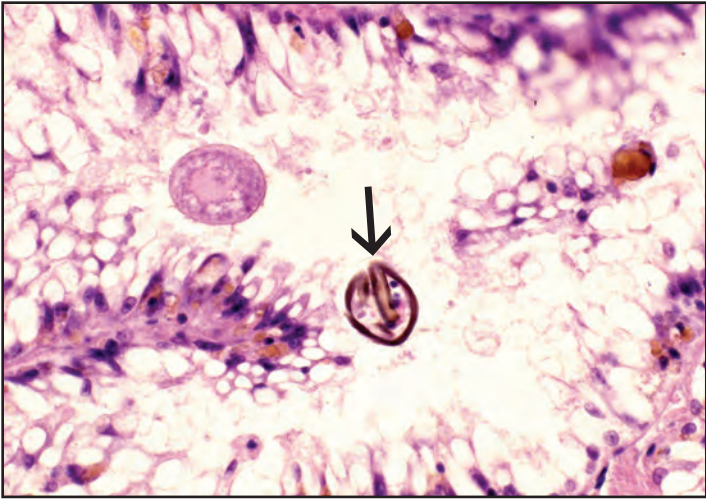
Unidentified Kidney Coccidia and Others



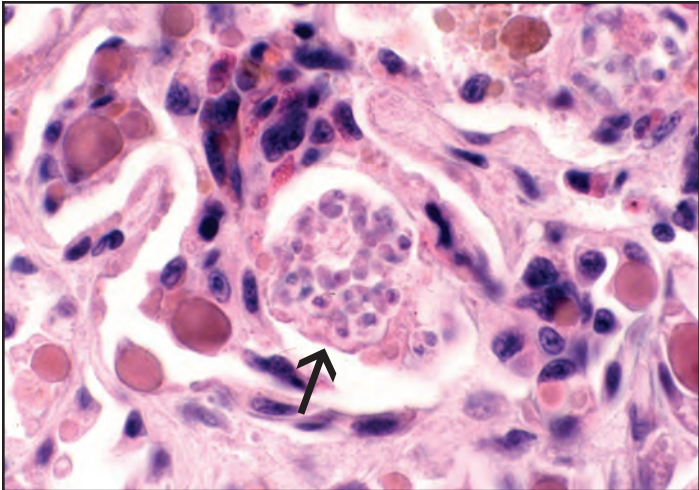
Histological section of gamonts (arrow) of a *Pseudoklossia*-like coccidian in the kidney of native littleneck clam



Microgamont (arrow) of a *Pseudoklossia*-like coccidian in the kidney of native littleneck clam

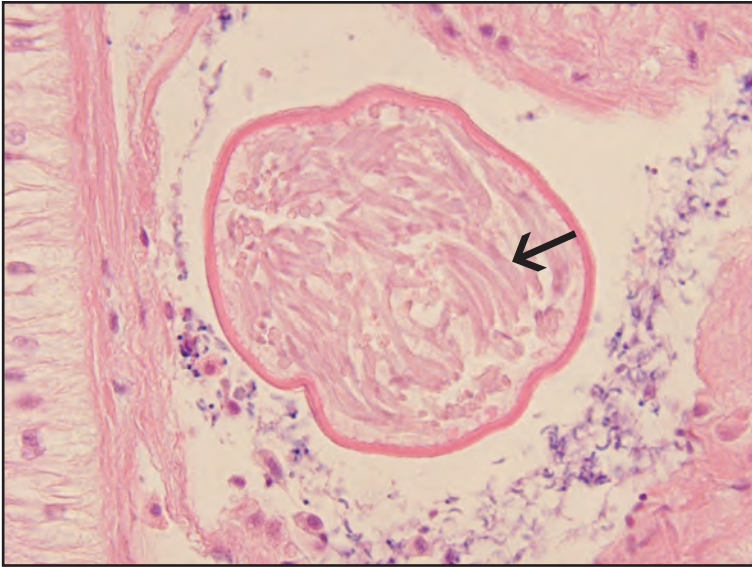


Resting spore (arrow) of *Pseudoklossia*-like coccidian in the kidney of native littleneck clam

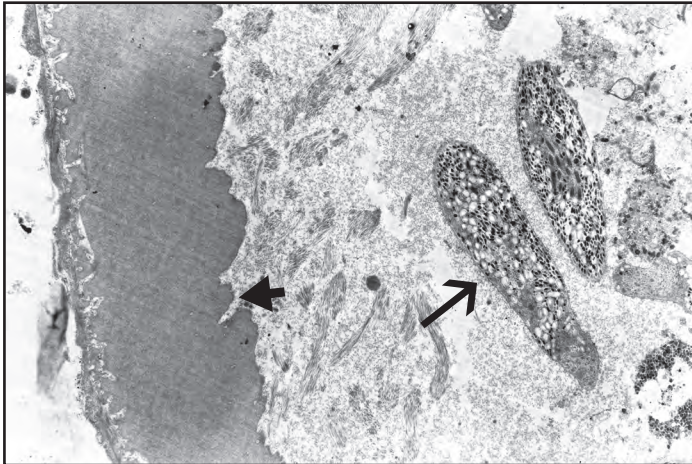


Oocyst (arrow) of *Pseudoklossia*-like coccidian in the kidney of basket cockle

Unidentified Kidney Coccidia and Others

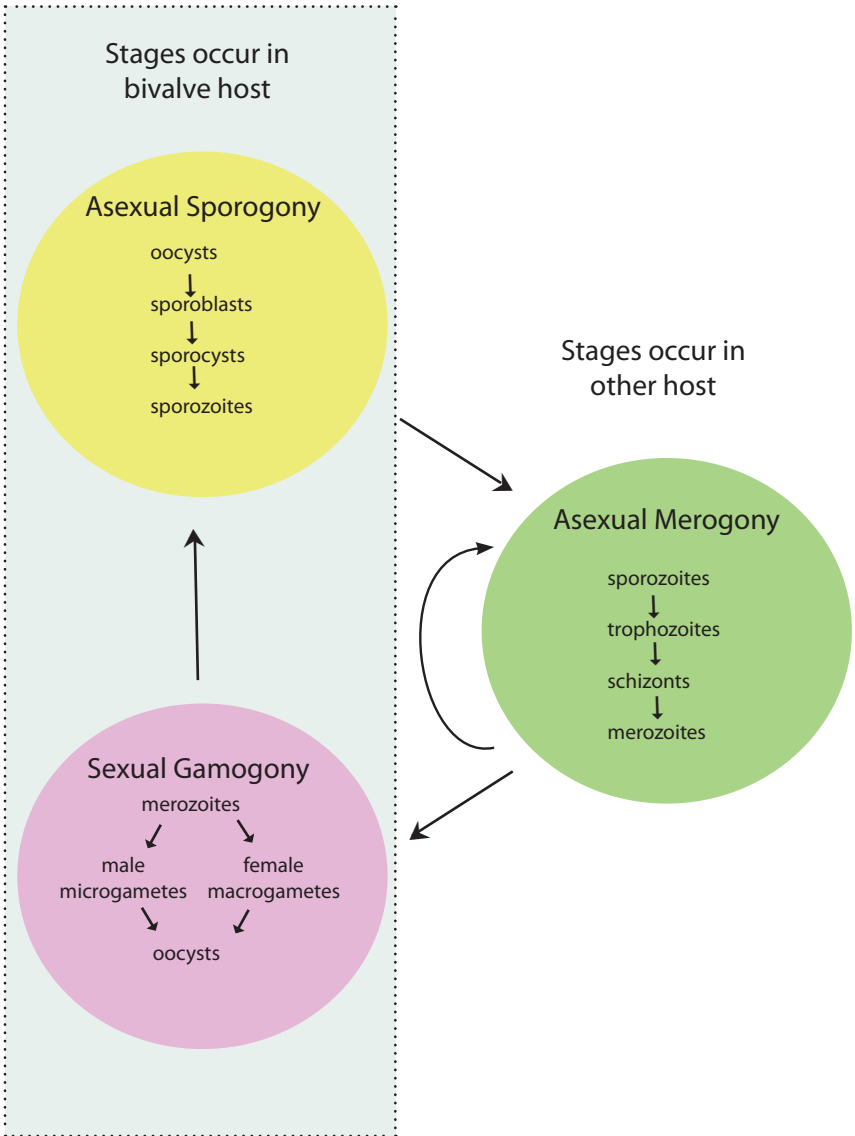


Histological section of sporocyst containing elongate sporozoites (arrow) of an unidentified coccidian in the connective tissue of native littleneck clam



Ultrastructural detail of littleneck clam sporozoites (arrow) and sporocyst wall (arrowhead), TEM

Typical Coccidia Life Cycle



Gill and Gut Turbellaria

I. Causative Agent and Disease

Turbellaria found associated with bivalve molluscs are flatworms of the phylum Platyhelminthes, class Turbellaria, order Rhabdozoa and family Graffillidae. These flatworms exist as both endocommensals and parasites able to pass freely between the mantle cavity and alimentary canal of the host bivalve. They generally are found in low prevalences and intensities causing no apparent harm to the bivalve host. A common species is *Urastoma cyprinae* found on the gills of several bivalve species or free-living in muddy sediments.

II. Host Species

Turbellarians have been reported from eastern oysters and giant scallops in Atlantic Canada, in various clams, cockles, mussels and oyster species in Europe and in geoduck clams and Pacific oysters in British Columbia, Canada. In Alaska, turbellaria have been observed on the gills, within alimentary tracts and kidneys of weathervane scallops, basket cockles, blue mussels and native little-neck clams. Turbellaria are likely global in distribution although individual species may be confined to certain ranges and bivalve hosts.

III. Clinical Signs

The only gross clinical signs of infestation may be the appearance of white to pink colored "gill worms" up to 2 mm long on gill and mantle surfaces.

IV. Transmission

Bivalve turbellarians are hermaphroditic having a direct life cycle where eggs are produced that hatch in ambient seawater. The juvenile stage may then

colonize another or the same host.

V. Diagnosis

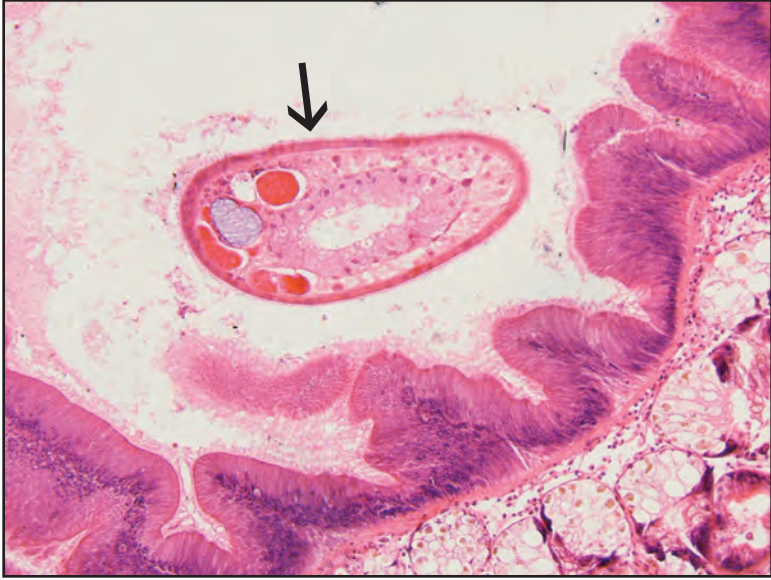Diagnosis is by observation of small, oval or pyriform worms up to 2 mm long having a ciliated body surface in wet mounts of gill or mantle tissues. Special stains of mounted worms are used for species identification. Also, routine histological examination may demonstrate the presence of ciliated flatworms in the intestinal tract, digestive tubules or kidney. The presence of external cilia differentiate turbellarians from other classes of flatworms.

VI. Prognosis for Host

Turbellarians cause no apparent harm to bivalve hosts.

VII. Human Health Significance

There are no zoonotic human health concerns with the presence of turbellarians on the surface or within shellfish tissues that may be consumed uncooked.



Histological section of a ciliated turbellarian (arrow) in the intestinal lumen of weather-vane scallop

Shell-Boring Polychaetes

I. Causative Agent and Disease

Segmented polychaete worms belong to the phylum Annelida, class Polychaeta and family Spionidae. These worms utilize the shells of bivalve molluscs as a substrate by constructing burrows on the shell surface or burrowing into the shell to form tunnels lined with compacted mud. Hence, the name of the condition is known as “mud blister”. The species *Polydora websteri* and *P. ligni*, among others, are commonly associated with mud blisters in bivalve molluscs causing unsightly internal shell surfaces and, in severe cases, causing formation of debilitating pustules or abscesses in soft tissues that can result in substantial bivalve mortality and economic losses.

II. Host Species

Shell-boring polychaetes occur worldwide causing mud blisters in various species of bivalve molluscs including oysters, mussels and scallops. In Alaska, mud blisters have only been observed in weathervane scallops from Shelikof Strait and may have been associated with mortality in the population.

III. Clinical Signs

Gross clinical signs include mud blisters on the inner surface of the shell and possibly yellow pustules in soft tissues contacted by the burrows. Severely infested bivalves may show gaping valves and an overall poor body condition. *Polydora ligni* does not bore directly into shell but builds tubes on the bivalve shell surface and secretes thick mucus that retains sediment, oyster feces and rejected material. Decomposition of this material produces hydrogen sulfide easily detected by odor that can also cause massive bivalve mortality.

IV. Transmission

The abundance of shell boring polychaetes is largely influenced by the presence of a mud bottom. Host infestation is from a simple direct life cycle. Juvenile worms settle on the edge of the shell and begin burrowing or, in the case of *P. ligni*, build their tubes on the surface of the shell. Hermaphroditic adults produce egg capsules in the burrow that hatch into larvae released into seawater which disperse to a new host.

V. Diagnosis

Diagnosis is based on gross observation of 2 mm diameter sinuous burrows or 1 cm diameter patches of mud and debris in or on the shell matrix when held next to a bright light. “Muscle pearls” or nacreous excrescences in the muscle scar of the shell is evidence of healed abscesses in the muscle tissues. A polychaete may be removed by breaking the shell along the burrow path and submerging the shell fragments in seawater to extract the worm with forceps and needle. Species identity is based on the morphological characteristics of the worm, particularly the armature of the setae.

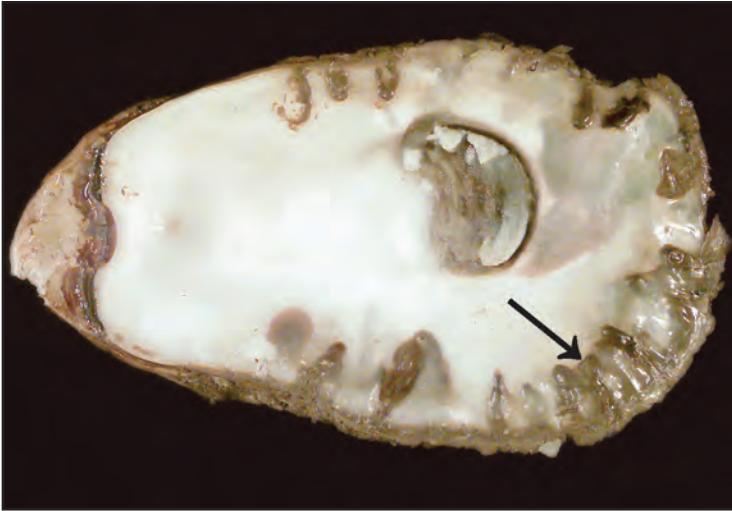VI. Prognosis for Host

Mortality of infested bivalves is generally rare when prevalences and intensities of mud blisters are low, but the half-shell marketability may be reduced. In the majority of cases oysters are able to better tolerate infestation by walling off the burrows with newly secreted shell nacre. Scallops are more seriously affected because they are less able to produce nacre towards the interior of the shell where burrows may damage the attachment of the adductor muscle. Violent

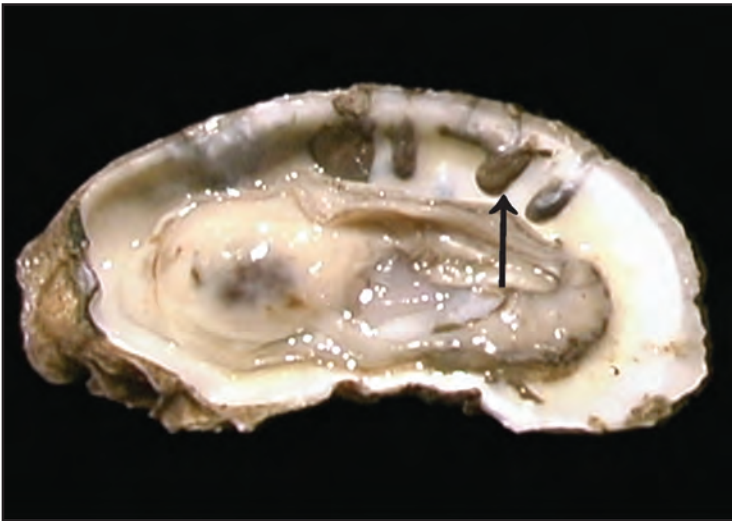
contractions of the valves can pull the damaged adductor muscle loose resulting in eventual scallop mortality. Prevalences and intensities of mud blister may be reduced by off-bottom bivalve culture techniques.

VII. Human Health Significance

There are no zoonotic human health concerns regarding polychaete infestation of bivalve molluscs except for the reduced aesthetic quality of meats consumed in the half-shell market.



Eastern oyster shell with *Polydora* tunnels (arrow) on inner surface of valves (Photo: Dorothy Howard, NOAA Cooperative Oxford, MD Laboratory)



Another eastern oyster with *Polydora* tunnels (arrow) on inner surface of valves (Photo: Dorothy Howard, NOAA Cooperative Oxford, MD Laboratory)

Trematode Metacercariae and Sporocysts

I. Causative Agent and Disease

Trematodes or flukes are members of the phylum Platyhelminthes and the class Trematoda. Adult worms of the subclass Digenea are endoparasites occurring in all classes of vertebrates and use invertebrates as the first and second intermediate host and rarely as the final host. A metacercaria is the encysted juvenile trematode usually occurring in the second intermediate host that requires ingestion by the final host to become an adult worm. A sporocyst is formed as part of the trematode developmental cycle in the first intermediate host. Depending on the trematode species, sporocysts and metacercariae are found in the tissues of a variety of intermediate hosts including bivalve molluscs. Low numbers of encysted metacercariae in most molluscs generally cause no overt disease but when present in significant numbers can cause general debilitation, behavioral changes favoring predation, tissue destruction and host death. Sporocyst stages are overtly destructive causing parasitic castration, weakness and gaping of valves with gradual destruction and replacement of molluscan tissues resulting in eventual mortality of the host. There are several different trematode families utilizing marine molluscs as intermediate hosts, most notably the family Bucephalidae and the genus *Bucephalus*.

II. Host Species

Various species of digenetic trematode sporocyst and metacercarial stages occur in many marine bivalve mollusc species worldwide including oysters, clams, scallops, mussels and cockles. In Alaska, sporocysts of unidentified trematodes have been observed in blue

mussels and razor clams while unidentified encysted metacercariae have been observed in blue mussels, basket cockles, littleneck clams and weathervane scallops.

III. Clinical Signs

Clinical signs of trematode sporocyst infestation may include increased flesh yield regarding initial sporocyst development that ultimately results in poor growth and debilitation in later stages, weakness in valve closure, reduced byssal thread production in mussels, infertility (parasitic castration), chalky shell deposits, induction of pearl formation reducing marketability and bivalve mortality. Encysted metacercariae most often are benign depending on the trematode species and intensity. However, some investigations have shown metacercariae to cause shell gaping and deformities, production of pearls and chalky shell deposits, behavioral changes that favor predation, reduced tolerance to stress, and host mortality in heavy infestations. Metacercariae and developing sporocysts may be observed in various bivalve tissues during routine histological examination.

IV. Transmission

Trematode life cycles involving marine molluscs generally include two intermediate hosts and one definitive host (only two hosts for Sanguinicolidae) with several possible combinations of pathways that include gastropods and bivalves (or other invertebrates) for intermediate hosts and fish, birds or bivalves (or other invertebrates) as final hosts. Trematodes of the family Bucephalidae are of great importance because their larvae affect numerous commercially

important mussels and oysters and food fishes such as flatfishes and cods. The pathway for *Bucephalus* sp. typifies the family and begins in a bivalve followed by a fish then on to a second fish as the final host. Eggs in the alimentary tract of the final predatory fish host are deposited with feces in seawater and hatch into ciliated miracidia that parasitize the first intermediate bivalve host. Once in the bivalve a miracidium develops into a mother sporocyst that produces more sporocysts that eventually produce cercariae released from the host. These cercariae drift with the currents and parasitize the second intermediate fish host and encyst as metacercariae. The encysted metacercariae find their way to the gut of the final host fish when the second intermediate fish host is eaten. Metacercariae become adult trematodes in the gut of the fish where eggs are produced to begin the cycle again. Encysted metacercariae found within bivalve host tissues indicate members of other trematode families that may follow different life cycle pathways of having a bivalve mollusc as a second intermediate host rather than a fish.

V. Diagnosis

Wet mounts of fresh tissues may show the encysted metacercariae (Gymnophallidae are unencysted) which can be extremely difficult to find if in low prevalences. Sporocysts of some trematodes may be grossly orange in color within the bivalve tissues and differentiated by species based on the morphology of the cercariae. Sporocysts and encysted metacercariae can also be observed in tissue sections during routine histological examination. Sporocysts may extensively infiltrate host tissues, exhibit dichotomous branching and are strongly basophilic containing germ balls and cercariae. Metacercariae may exhibit trematode features such as oral and ventral suckers and appear in various tissues

as small foci having varying degrees of encapsulating host fibrous tissues and inflammatory cells.

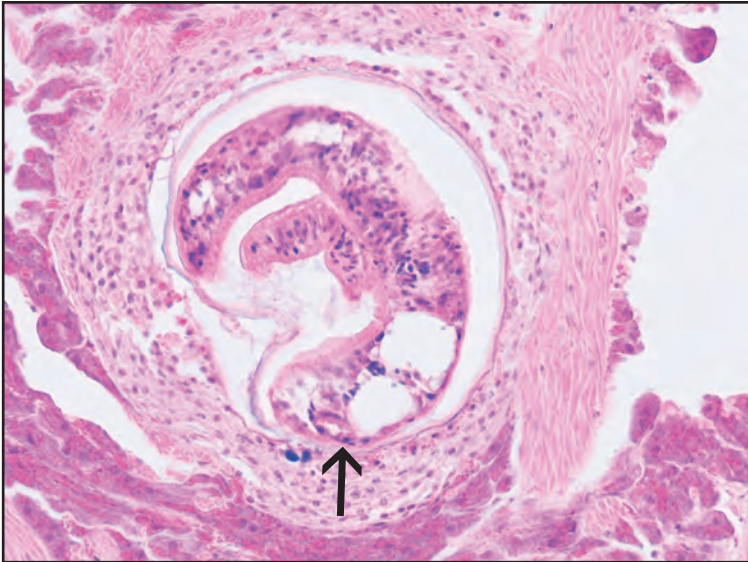
VI. Prognosis for Host

Effects of encysted metacercariae on the bivalve host vary from none to being responsible for killing young spat. In the Pacific Northwest and Alaska, metacercariae are considered relatively harmless to bivalve hosts except when encountered in significant numbers. Sporocysts may cause severe tissue damage and debilitation resulting in parasitic castration and bivalve mortality.

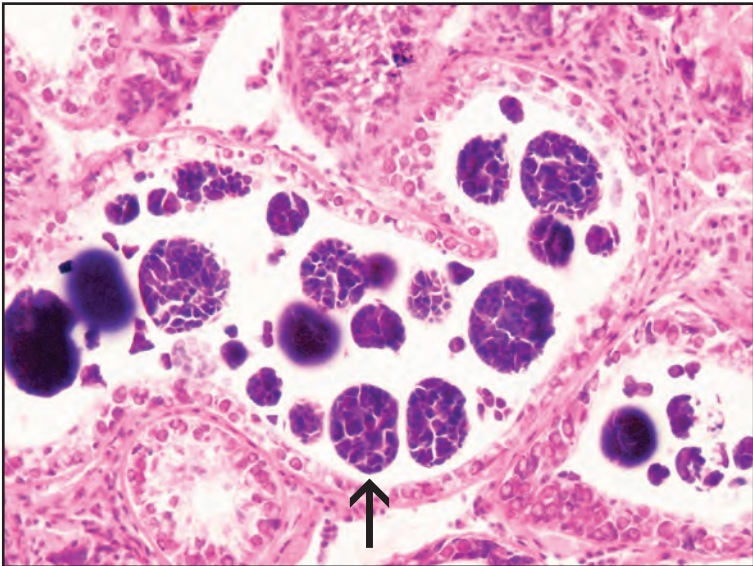
VII. Human Health Significance

Trematodes in the family Echinostomatidae parasitize birds as the final host. Echinostome metacercariae, such as *Himasthla* sp., found in bivalve tissues consumed raw have been implicated in human gastrointestinal disturbances.

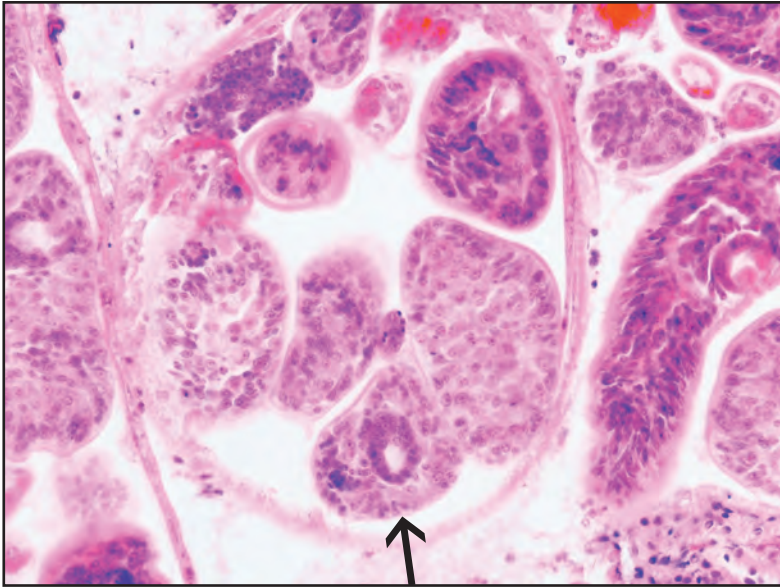
Trematode Metacercariae and Sporocysts



Histological section of encysted trematode metacercaria (arrow) encapsulated by host inflammatory cells and fibrous tissue within the connective tissues of blue mussel

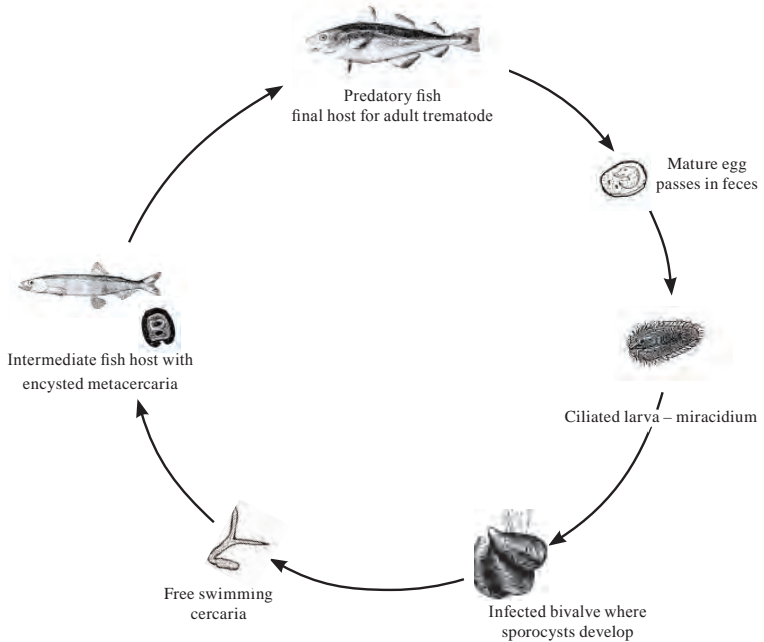


Histological section of a *Bucephalus*-like trematode sporocyst containing germ balls (arrow) in the connective tissues of blue mussel



Histological section of a different type of sporocyst containing cercariae (arrow) in razor clam

Bucephalus sp. Life Cycle



Gill and Gut Parasitic Copepods

I. Causative Agent and Disease

Parasitic copepods are arthropods belonging to the subphylum Crustacea, class Maxillopoda and subclass Copepoda. Copepods parasitizing bivalve molluscs are mostly within the order Cyclopoida and can be divided into two basic groups; obligate endoparasites inhabiting the alimentary tract including the more common species of *Mytilicola* (*intestinalis*, *orientalis*, *porrecta*) and ectoparasites inhabiting the mantle and gill tissues including several species within the genera *Conchyliurus*, *Modiolicola*, *Mycicola*, *Myocheres*, *Ostrincola*, *Pseudomyicola* and *Paranthessius*. An exception to the latter group is *Pseudomyicola spinosus* that apparently is able to move back and forth between the gill/mantle areas and the alimentary tract of bivalve hosts. *Mytilicola* has been implicated in causing intestinal damage, poor growth and mortality in European mussels but conclusive evidence is lacking regarding its true pathogenicity. Most ectoparasitic copepods appear to be commensals but their attachment to gill surfaces may cause localized tissue damage. When found within the GI tract, *P. spinosus* may damage mucosal epithelial cells followed by perforation, subsequent invasion into connective tissues and encapsulation of the parasite by host granulomatous tissues.

II. Host Species

Mytilicola intestinalis is apparently limited to Europe occurring in mussels, clams, cockles and the flat oyster in waters from Denmark to Italy including the British Isles and Ireland but not the Baltic. *Mytilicola orientalis* was introduced to the Pacific Northwest and

Canada with seed oysters from Japan. It occurs in the European flat, Pacific and native oysters and several other species of marine bivalves and has recently been introduced into France. *Mytilicola porrecta* occurs in ribbed and hooked mussels and may also occur in other bivalves in the Gulf of Mexico. External parasitic copepods have been reported in the mantle and on the gills of various bivalve species from Europe and from the Atlantic, Gulf and Pacific coasts of North America, including British Columbia, Canada. In Alaska, unidentified parasitic copepods have occurred on the gills and in the alimentary tracts of Pacific oysters, basket cockles, blue mussels, rock scallops and native littleneck clams. Many of these copepods have been present both externally and internally appearing more like *Pseudomyicola* rather than *Mytilicola*.

III. Clinical Signs

Copepod infestations are mostly found by routine histological examination. There are no clinical signs of external or internal copepod infestation except in European reports attributing poor growth and mortality in mussels to infestations by *M. intestinalis*. Infestations in the GI tract may cause metaplasia (columnar epithelium reduced to low cuboidal or squamous) of mucosal epithelium and in rare cases erosion and perforation from the appendages with or without host encapsulation by hemocytes.

IV. Transmission

Parasitic copepods of bivalve molluscs have a direct life cycle involving copulation of two adult sexes and the production of eggs that hatch directly in

ambient seawater or, as with endoparasitic species, the egg cases are released with feces to seawater. The hatched nauplii may undergo molts into other naupliar stages or into metanauplii and finally to one or more copepodid stages. One of the copepodid stages is usually the initial parasitic stage that either attaches to the external target host tissue or, in the case of endoparasitic forms, is drawn into the GI tract by filter feeding of the mollusc host. Other parasitic instars may occur until the copepod becomes an adult. However, the number of molts and specific stages vary depending on the species of parasitic copepod and remain unknown for many.

V. Diagnosis

Specific diagnosis is based on observing external copepods attached to gills and mantle tissues or by dissecting reddish colored elongate worm-like copepods from the stomach and intestine of internally infested bivalves. Enzymatic digestion also may be used for quantification. The body of *Mytilicola* sp. is about 5 to 12 mm long (depending on species), relatively dedifferentiated with reduced limbs and body segmentation and overall is less recognizable as compared to other ectoparasitic genera that resemble free living copepods. Species is determined by various external morphological features (body length or size, mouth parts and antennae) of female copepods since the occurrence of males is generally transient. Histological examination of a parasitic copepod demonstrates general features of a complex body structure with carapace, segments, appendages, GI tract, gonads and striated musculature.

VI. Prognosis for Host

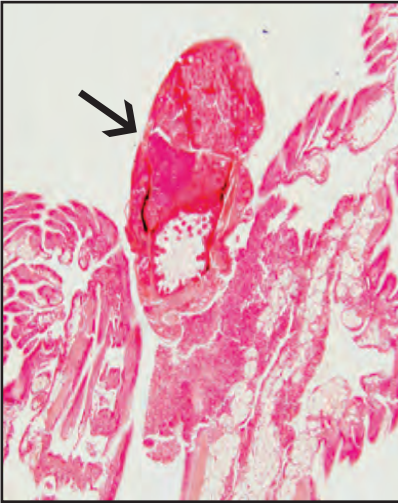
The effects of ectoparasitic copepods on their hosts have been minimal and generally considered harmless, unless

the parasites are present in great numbers. The pathogenicity of endoparasitic copepods in bivalve molluscs has been enigmatic with many reports indicating no pathogenicity. Other investigators indicate poor growth and bivalve mortality caused by erosion of the mucosal epithelium with perforation and encapsulation of the parasites in surrounding connective tissues. Internal copepods may also cause apparent occlusion of the large ducts connecting the stomach and digestive diverticulae. *Mytilicola* sp. occurs more commonly in larger host animals inhabiting the bottoms of sheltered areas and rarely occurs in bivalves less than 10 mm in length and in Pacific oysters less than or equal to 20 mm. In Alaska, there has been no bivalve mortality or poor body condition associated with the presence of parasitic copepods.

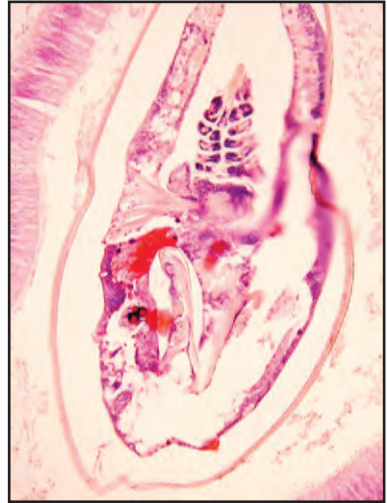VII. Human Health Significance

There are no zoonotic human health concerns with the occurrence of parasitic copepods in the tissues of bivalve molluscs.

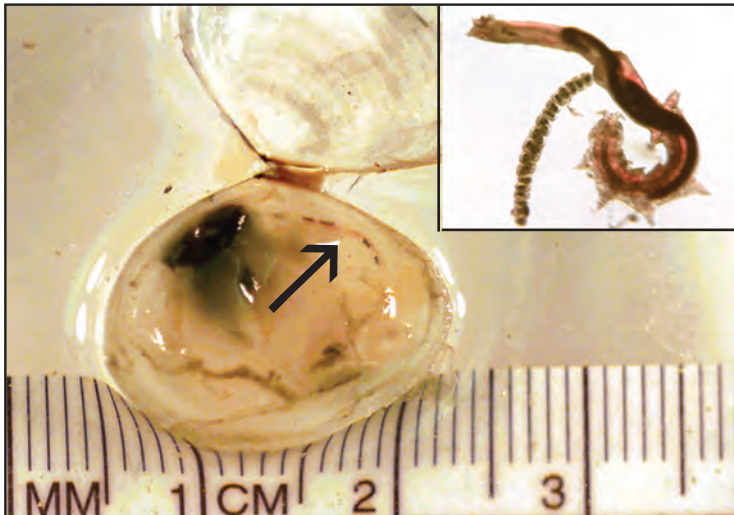
Gill and Gut Parasitic Copepods



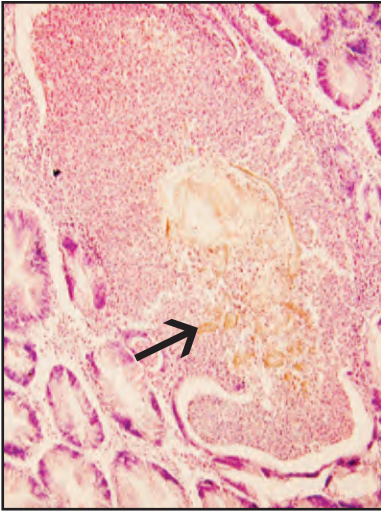
Histological section of Pacific oyster with a parasitic copepod (arrow) attached to the gill tissues causing localized inflammation



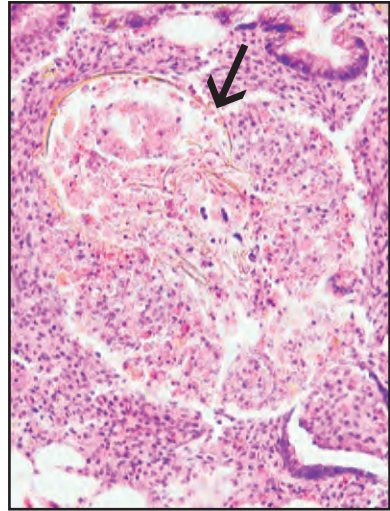
Histological section of Pacific oyster with a parasitic copepod in the intestinal lumen



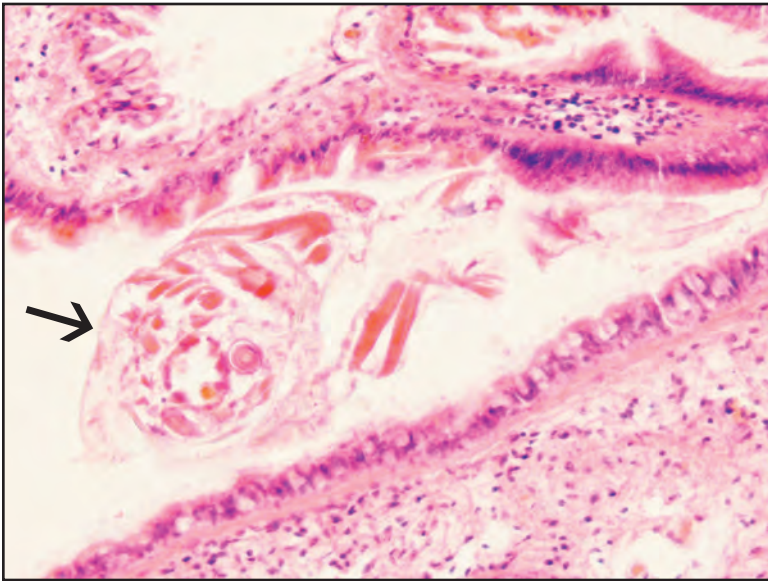
Mytilicola sp. in gut (arrow and inset) of the clam *Macoma balthica* (Photo: Dorothy Howard, NOAA Cooperative Oxford, MD Laboratory)



Histological section of dead parasitic copepod (arrow) surrounded by host inflammatory cells after penetrating into the connective tissues from digestive gland tubules in Pacific oyster



Similar dead parasitic copepod (arrow) surrounded by host inflammatory cells in connective tissue of digestive gland of blue mussel



Histological section of a parasitic copepod (arrow) on the mantle tissues of weather-vane scallop

Foreign Body Granulomas and Pearls

I. Causative Agent and Disease

Foreign body granulomas are inflammatory cell foci within host tissues in response to a non-self object or irritant. These granulomas are usually benign and are found incidentally when examining histologic sections of bivalve molluscs. The foreign body stimulating the formation of a granuloma often cannot be identified by examining the section due to degradation by the host response or because it is outside the plane of section. Foreign bodies that cause granulomas most commonly include trematode metacercariae, cestode and nematode larvae and parasitic copepods (see other chapters). Bacterial, fungal and protozoan agents may also be responsible for granulomas as well as inert material that may become embedded in shellfish tissues. Pearls are calcium carbonate concretions precipitated in the soft tissues by bivalve molluscs in response to the same irritants or foreign bodies that cause granulomas.

II. Host Species

Unidentified foreign body granulomas and pearls may be found in a variety of marine and freshwater bivalve mollusc species worldwide including clams, oysters, cockles, scallops and mussels. In Alaska, foreign body granulomas have been observed in Pacific oysters, blue mussels, basket cockles, littleneck clams and weathervane scallops while pearls have been found in weathervane scallops, Pacific oysters and most commonly in the blue mussel.

III. Clinical Signs

Generally, there are no obvious clinical signs of either foreign body granulomas or pearls, both of which are too

small to be observed except when tissues are examined histologically.

IV. Transmission

Additional details regarding transmission of metazoan parasites and Sporozoa that may cause either unidentified foreign body granulomas and/or pearls may be found in other sections of this booklet. Granulomas and pearls caused by non-infectious foreign bodies (sand, shell, debris) occur spontaneously and are not transmissible. An exception is found in the Japanese pearl industry where artificial transmission of a non-infectious foreign body is accomplished by manual insertion of nacreous shell material between the mantle layers of pearl oysters. These shell chips cause tissue irritation that is walled off by calcareous secretions which form cultured pearls.

V. Diagnosis

Diagnosis of unidentified foreign body granulomas and pearls is generally made by routine histological examination. Granulomas are composed of variably sized foci of host inflammatory cells sometimes surrounding a necrotic center. Pearls appear as eosinophilic layered concretions within soft host tissues, most often the mantle.

VI. Prognosis for Host

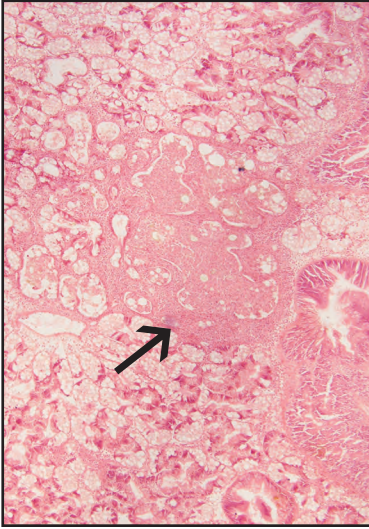
Unidentified foreign body granulomas and pearls in bivalve molluscs are considered benign unless present in large numbers that may impair normal tissue functions. High intensities of metacercarial infestation that may cause either or both conditions can result in host mortality and debilitation. However, in the

Pacific Northwest and Alaska, trematode metacercariae are usually encountered at low prevalences and intensities causing no significant harm to bivalve hosts.

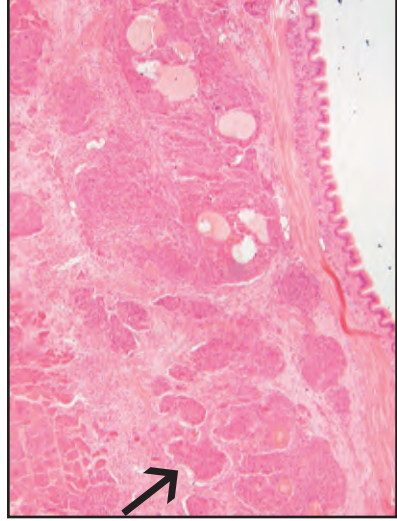
VII. Human Health Significance

Unidentified foreign body granulomas and pearls in bivalve molluscs are of no direct zoonotic human health concern. Bivalve tissues containing high numbers of calcareous pearl concretions

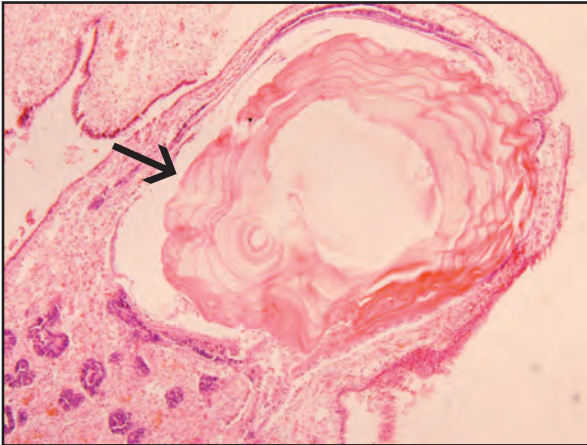
may be unfit for human consumption for obvious reasons. Some concern may be warranted in cases where metacercarial infestation is implicated as causing granulomas or pearls. Echinostome metacercariae, such as *Himasthla* sp., have been implicated in human gastrointestinal disturbances when present in bivalve tissues consumed raw.



Unidentified foreign body granulomas (arrow) encompassing digestive tubules in weathervane scallop, histological section



Unidentified foreign body granulomas (arrow) in the mantle connective tissue of blue mussel, histological section



Histological section of a pearl (arrow) with concentric layers in the mantle tissue of blue mussel

Miscellaneous Invertebrate Pests and Predators

I. Causative Agent and Disease

Marine invertebrates that are considered pests and predators do not necessarily cause disease. They may kill bivalve molluscs by directly feeding on them or use them as a substrate which inadvertently causes debilitating damage that may affect the health of the bivalve or its marketability. Besides the numerous biofouling organisms other known pests of bivalves in Alaska include three species of pea crabs found inhabiting the mantle cavities of several bivalves and the introduced non-indigenous boring sponge, *Cliona thooosina*, that uses the external shell of several bivalve molluscs as a substrate. Common invertebrate predators of bivalves in Alaska include starfish and various species of crabs, most notably of the genus *Cancer*. Although two snail species of oyster drill are present in the Pacific Northwest, there have been no confirmed reports that either has become established in Alaska through importation of Pacific oyster spat.

II. Host Species

Upper ranges of pea crabs in Alaska, depending on species, include Akutan, Prince William Sound and Prince of Wales Island and are most commonly found in the mantle cavities of mussels, horse clams and occasionally other bivalve species. Boring sponge was introduced into Prince William Sound and can occur on various substrates including the shells of several bivalve molluscs, most notably Pacific oysters. Various starfish species and numerous species of crabs are common marine fauna throughout Alaska and opportunistically feed on any available species of bivalve mollusc.

III. Clinical Signs

Physical presence of the pest or predator is obvious causal evidence but in their absence there are occasional clinical signs to indicate they have been there. Signs of pea crab infestation can include minor damage or atrophy of mantle and gill tissues. Boring sponges burrow into calcium carbonate by localized secretion of enzymes that etch bivalve shells causing many small holes and a porous appearance. The stomach of a starfish is everted between the valves of a mollusc to digest the soft tissues leaving the empty cleaned valves. Crab predation generally leaves a jagged to rounded hole in one of the empty valves of the eaten bivalve. Although drills have not been reported in Alaska, these snails bore through the shell leaving a small perfectly round hole with an indented margin from the scouring action of their rasping mouthpart, known as a radula.

IV. Transmission

Invertebrate pests and predators are normal fauna of the marine environment that reproduce in the water column. Adult crabs and starfish are mobile and able to seek out hosts or prey. Boring sponges are disseminated horizontally in ambient water by sexual reproduction producing planktonic larvae or asexually by formation of spore-like gemmules or fragmentation and/or budding from the main sponge body that drift and settle elsewhere.

V. Diagnosis

Diagnosis is based on observation of clinical signs or physical presence of the pest or predator.

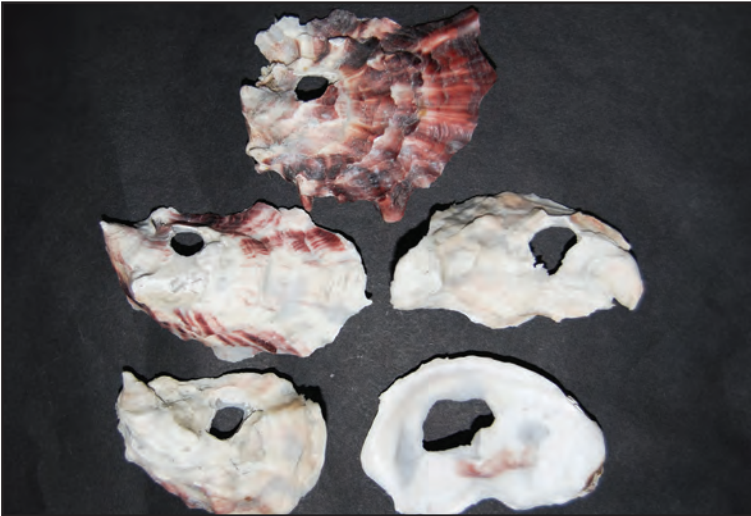VI. Prognosis for Host

Predators generally kill their prey. Pests may debilitate or weaken their hosts. Pea crabs are generally benign pests. Boring sponge can weaken the host shell that may increase vulnerability to predation or in the worse case dissolve the shell killing the host. Oysters with shells scarred by boring sponge generally are not marketable. There is always risk of introducing bivalve pests, preda-

tors and pathogens alike into new areas by the importation of shellfish such as Pacific oysters.

VII. Human Health Significance

There is no zoonotic human health concern with the presence of invertebrate predators or pests associated with bivalve molluscs except for the potential loss of aesthetic quality to the consumer.

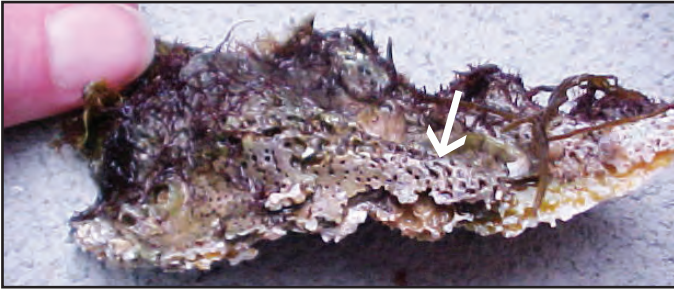

Irregular to round holes in the shells of juvenile Pacific oysters produced by crab predation



Japanese oyster drill eggs on the shell of an adult Pacific oyster (Photo: R. Elston, AquaTechnics, WA)

Miscellaneous Invertebrate Pests and Predators



Boring sponge etching (arrow) on the external shell of a Pacific oyster (Photo: R. Elston, AquaTechnics, WA)



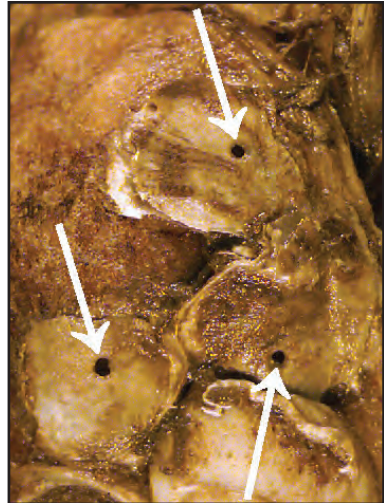
Boring sponge etching (arrow) that has penetrated to the internal shell surface of the same oyster (Photo: R. Elston, AquaTechnics, WA)



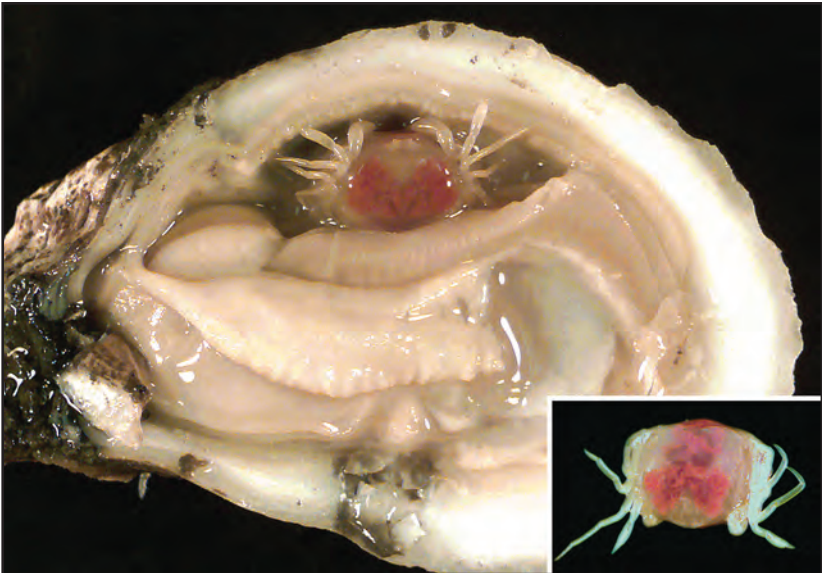
Starfish predation on bay scallop (Photo: Dorothy Howard, NOAA Cooperative Oxford, MD Laboratory)



Oyster drill *Urosalpinx cinerea* (Photo: Dorothy Howard, NOAA, Cooperative Oxford, MD Laboratory)



Drill holes (arrows) in shells of the eastern oyster (Photo: Dorothy Howard, NOAA Cooperative Oxford, MD Laboratory)



Pea crab (*Pinnotheres*) in the gill mantle cavity of an eastern oyster (Photo: Dorothy Howard, NOAA Cooperative Oxford, MD Laboratory)

Neoplasia (Tumors)

I. Causative Agent and Disease

Cancers or neoplasms are growths of abnormal cells that proliferate uncontrollably. In bivalve molluscs, neoplasms are rare in comparison to vertebrates but more common than in other invertebrate phyla. Neoplastic lesions have been reported most commonly in oysters but also in other marine clams and mussels including mesenchymal tumors, epithelioma, myofibroma, germinoma, neurofibroma, sarcomas and disseminated neoplasia resembling leukemia. Bivalve molluscs develop cancer in much the same way as do higher animals. Known and suspected factors contributing to neoplasia in molluscs include viruses, environmental chemicals (carcinogens), repeated physical trauma, hormones, age, sex and genetic predisposition.

II. Host Species

Neoplasia has been reported in: Pacific and Olympic (native) oysters on the Pacific coast of North America as well as the eastern oyster on the Gulf and Atlantic coasts; ocean quahog, hard and soft-shell clams and bay scallop on the Atlantic coast; Pacific oyster and mussel in Japan; pearl oyster in Australia; Chilean oyster in Chile and New Zealand; the European flat oyster in Spain and Yugoslavia; the common cockle in Ireland and Spain; the Mediterranean mussel in Spain; the blue mussel in Great Britain, Scandinavia, Tasmania and North America including British Columbia, Canada. Disseminated neoplasia is reported to occur in at least 15 marine bivalve species from four continents and every ocean except the Antarctic. In Alaska, neoplasms observed in bivalve molluscs have included germinoma (gonadal origin) in an adult Pacific oyster,

mesenchymal (connective tissue origin) tumor in a blue mussel, disseminated neoplasia (hemocyte origin) in a blue mussel and littleneck clam and a secretory cell adenoma of the gill arch in a geoduck clam.

III. Clinical Signs

Clinical signs of neoplasia may include a grossly visible abnormal tissue mass but more commonly neoplasia in bivalve molluscs is an incidental finding during routine histological examination. High prevalences of disseminated or hemic neoplasia in blue mussels and soft shell clams have been associated with significant mortality of 30-80%.

IV. Transmission

Most neoplasms described in bivalve molluscs are considered spontaneous resulting from environmental contamination, congenital malformation, age or genetic predisposition and are not transmissible in nature. A major exception is disseminated neoplasia in clams, mussels and cockles which has been transmitted in mussels by cohabitation and in mussels and cockles by injection of cancerous cell-free tissue homogenates suggesting an infectious agent. In soft-shell clams mixed results using cell-free homogenates are reported but a retrovirus is suspected to cause the disease in all three bivalve species. The highest prevalences of disseminated neoplasia occur during autumn and winter months with highest bivalve mortality occurring in late winter and early spring.

V. Diagnosis

Neoplasms are diagnosed and classified using histological methods to determine the cell or tissue of origin and

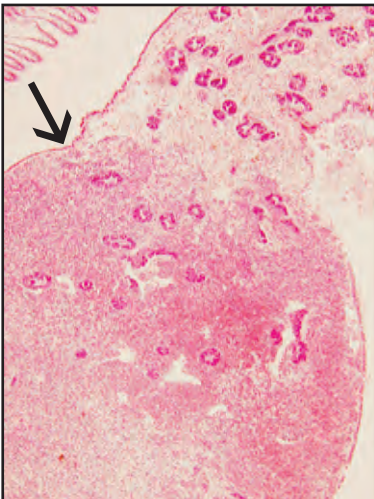
are further grouped based on benign or malignant characteristics. Benign tumors are often well-differentiated, grow slowly, are well circumscribed without invading surrounding normal tissue and do not metastasize. Most benign neoplasms usually end in the suffix “oma”. Exceptions are benign neoplasms of the brain and some endocrine organs in higher vertebrates that can be life threatening due to their location and deleterious physiological effects on the host. Malignant tumors are often not well differentiated, may grow rapidly, infiltrate normal tissues and tend to metastasize. The names of these neoplasms are often preceded by the word “malignant” or with the suffixes “sarcoma” or “carcinoma”. Disseminated neoplasia in bivalve molluscs is characterized by intense infiltration of tissues by abnormal hemocytes that have very little cytoplasm and enlarged pleomorphic nuclei with frequent mitotic figures. The neoplastic cells can be examined from wet and stained preparations of collected hemolymph and during histological examination of cut tissue sections.

VI. Prognosis for Host

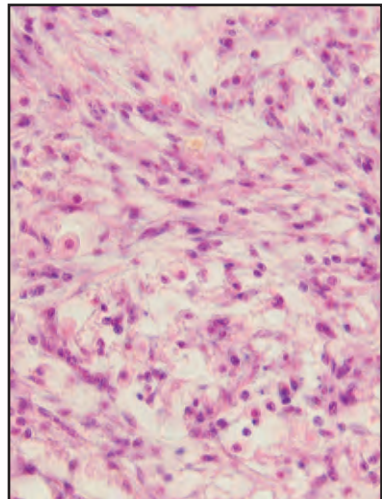
Neoplasia usually results in death of the affected bivalve mollusc, although remission has been known to occur with disseminated neoplasia. High prevalences of disseminated neoplasia are associated with high mortality of bivalve mollusc populations, especially those that have been previously unexposed. Due to the transmissible nature of this cancer, known infected stocks of bivalve molluscs should not be introduced to new areas.

VII. Human Health Significance

Although aesthetically disturbing, there are no zoonotic human health concerns associated with neoplasia in bivalve molluscs. Except for disseminated neoplasia that has a suspected viral etiology, cancer is generally a rare event in bivalve molluscs affecting one animal in several thousand. Should these other tumors occur more frequently in a population, an indirect human health concern would be whether the cause is linked to environmental contamination.

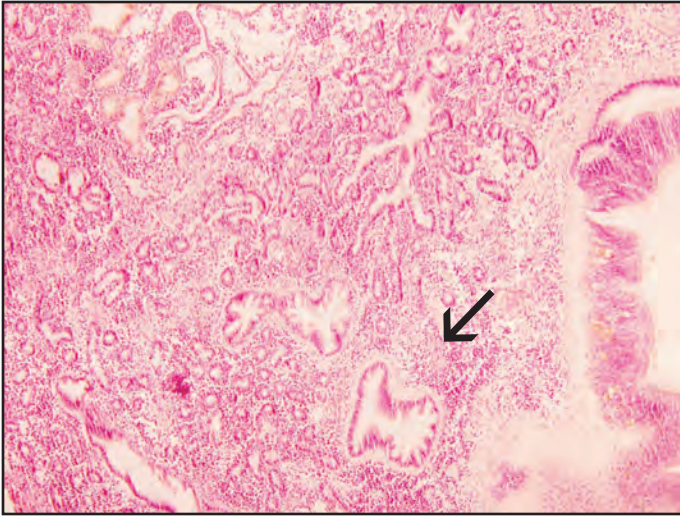


Histological section of mesenchymal neoplasm (arrow) in blue mussel

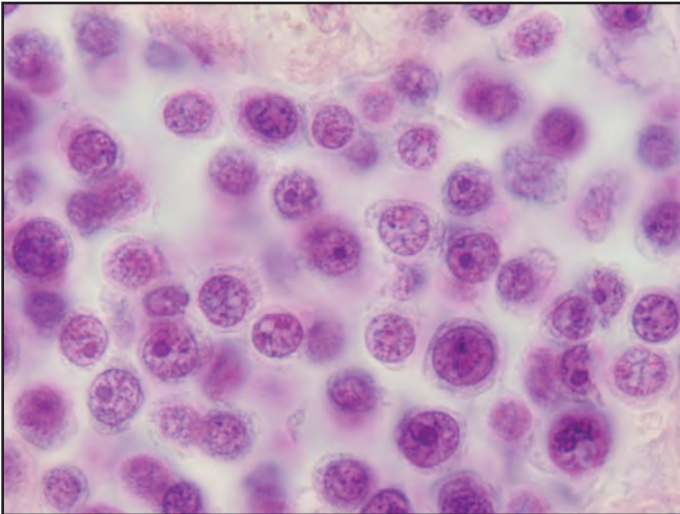


Higher magnification of fibroblastic type cells composing the mesenchymal neoplasm

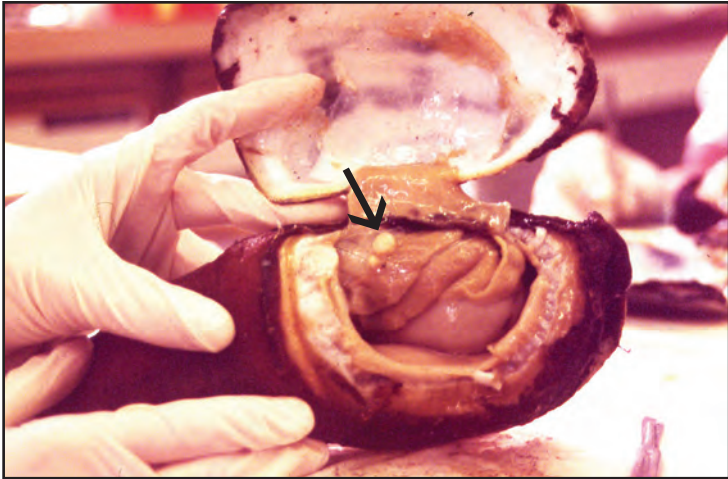
Neoplasia (Tumors)



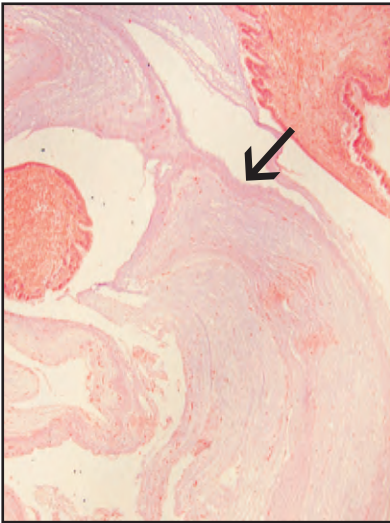
Histological section of disseminated neoplasia (arrow) in blue mussel



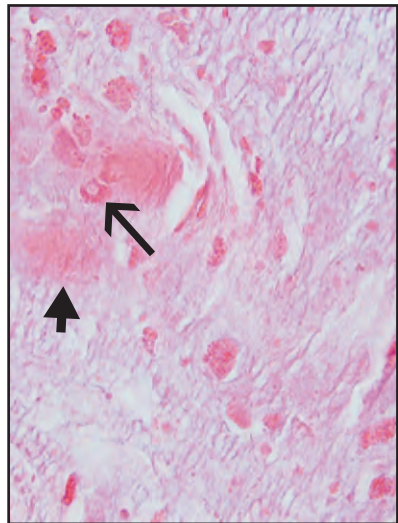
Higher magnification of typical leukemic-like cells with large nuclei and scant cytoplasm comprising disseminated neoplasia



Two white nodular foci (arrow) of a secretory cell adenoma on the gill arch of a geoduck clam



Histological section of geoduck adenoma composed of concentric whorled layers of basophilic mucinous material (arrow) containing secretory type cells and areas of collagen



Higher magnification of collagen (arrowhead) and secretory-type cells (arrow) containing eosinophilic droplets also found free in the tumor mass

Aquabirna and Herpes Viruses

I. Causative Agent and Disease

Many different viruses occurring in wild shrimp and crabs have been described globally but few have been documented in Alaska. In part this may be due to the paucity of studies conducted on wild crustacean populations, the geographic isolation of Alaska and the absence of a commercial mariculture industry for shrimp that has prevented importation of exotic crustacean viruses from other parts of the world. Two viruses have been reported from king crabs in Alaska, a herpes-like virus and an aquabirna-like virus, while suspicious intranuclear inclusion bodies have been observed in Dungeness crabs.

A herpes-like virus reportedly infects the bladder and antennal gland epithelium in red, blue and golden king crabs. The virus nucleocapsid is 140 X 165 nm in diameter with two electron-dense layers surrounding a central electron-dense cylinder of approximately 55-60 X 90-105 nm. Enveloped particles were not observed by transmission electron microscopy and no other biochemical features are known. An aquabirna-like virus was reported infecting labyrinth epithelium of the antennal gland from a single asymptomatic blue king crab. The virus particles were icosahedral, about 65 nm in diameter and present within cytoplasmic inclusion bodies containing microtubular structures. Intranuclear inclusion bodies of possible virus origin have been observed in the cells of the urinary bladder, hepatopancreas and female seminal receptacle of Dungeness crabs.

II. Host Species

The herpes-like virus infects blue, red and golden king crabs from Cook In-

let, Bristol Bay, Pribilof Islands and the western Aleutian Islands. The aquabirna-like virus was found in a single male blue king crab from Glacier Bay in southeast Alaska while the intranuclear inclusions were observed in 4% of the Dungeness crabs collected from Excur-sion Inlet, Freshwater Bay and Bridget Cove near Juneau.

III. Clinical Signs

No outward or internal clinical signs are reported for either virus. The herpes-like virus is associated with massive destruction of the bladder, antennal gland and sometimes hindgut epithelium, strongly suggestive of a lethal disease. The aquabirna-like virus was contained within cytoplasmic inclusion bodies in the labyrinth epithelium of the antennal gland. In the same tissue an adenocarcinoma (discussed in other section) of probable tegmental gland epithelial origin was also present. However, there is no evidence that the virus was the cause of or otherwise was specifically associated with the neoplasm. The intranuclear inclusions in Dungeness crabs were incidental findings on routine histological examination.

IV. Transmission

The mode of transmission is unknown for either virus but suspected to be horizontal from animal to animal via ambient seawater.

V. Diagnosis

Neither virus has been isolated in cell culture. The herpes-like virus infection is recognized by cytopathology in histological sections comprised of hypertrophied epithelial cell nuclei of the bladder and antennal gland. Examina-

tion by TEM confirms that the enlarged nuclei contain marginated chromatin, a rarified eosinophilic stroma with one or more pleomorphic eosinophilic inclusion bodies associated with typical herpes-like virus particles scattered throughout the nuclear stroma. TEM confirmation of virus particles has been done for only one such diseased blue king crab. The aquabirna-like virus may have been an incidental subclinical finding that was only recognized by serendipitous observation with TEM unless the grossly visible neoplasm was somehow virus-associated. The intranuclear inclusion bodies in the Dungeness crabs were detected by histological examination.

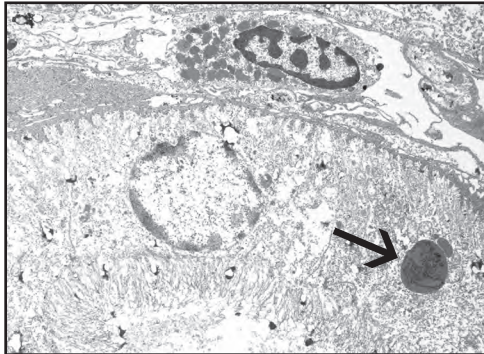
These inclusions were basophilic causing nuclear enlargement, compression and eccentricity of the nucleoplasm and nucleolus with margination of chromatin.

VI. Prognosis for Host

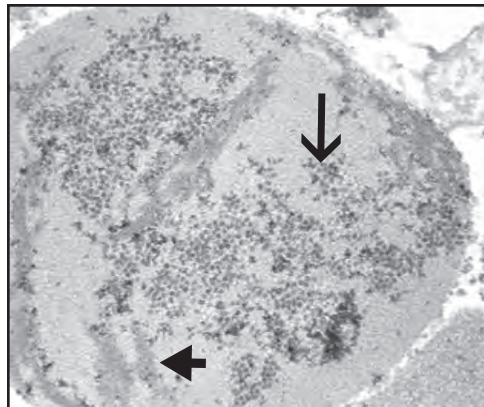
The host prognosis regarding infection by either virus is unknown but the herpes-like virus is suspected to cause king crab mortality.

VII. Human Health Significance

There are no known zoonotic human health concerns associated with infection of king or Dungeness crabs by poikilothermic viruses.

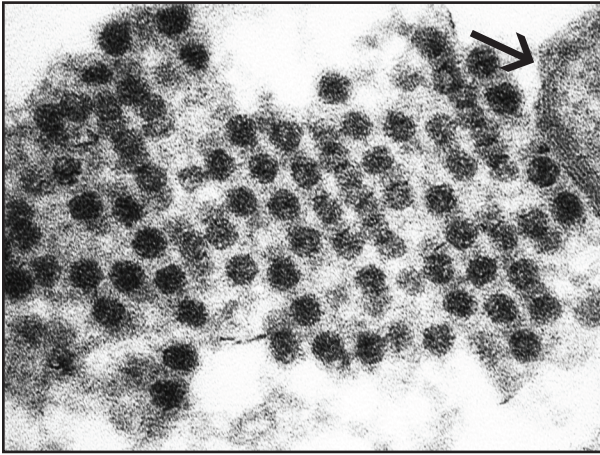


TEM of a labyrinth epithelial cell of the antennal gland in blue king crab with cytoplasmic inclusion (arrow)

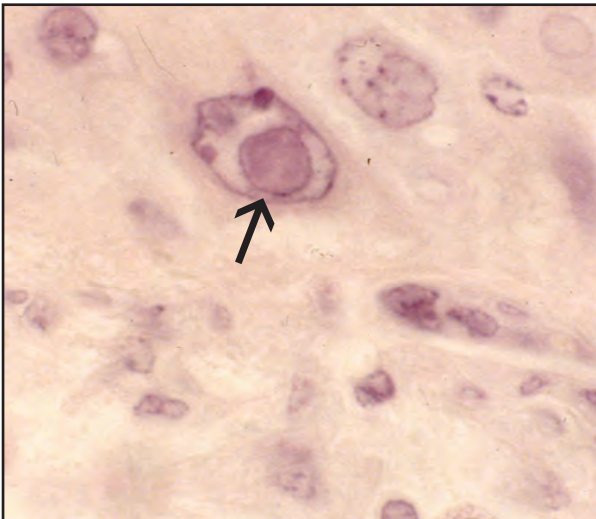


Higher magnification of inclusion showing icosahedral aquabirna-like virus particles (arrow) with associated microtubular structures (arrowhead)

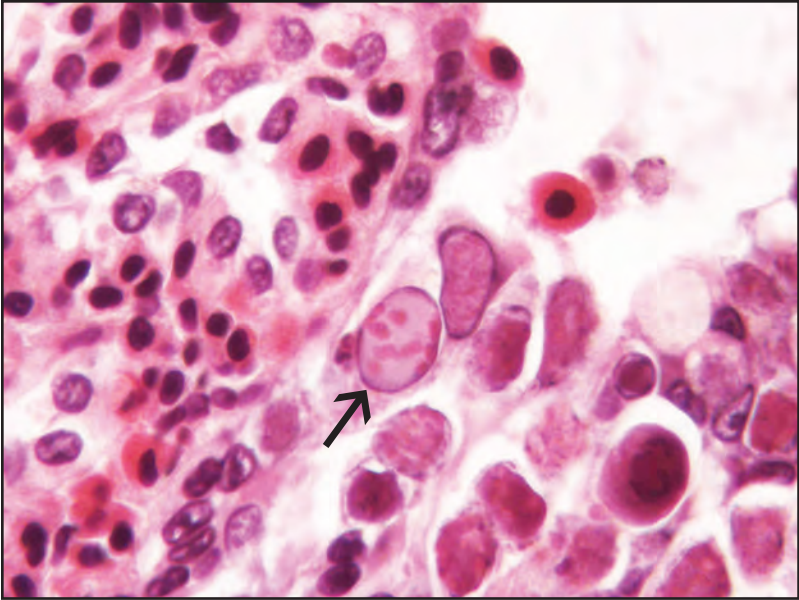
Crustacean Viruses




Higher magnification of blue king crab aquabirna-like virus particles with associated microtubular structure (arrow)



Histological section of intranuclear inclusion body (arrow) in a bladder epithelial cell of Dungeness crab



Histological section of blue king crab antennal gland epithelium with hypertrophied nuclei (arrow) containing one or more eosinophilic intranuclear inclusion bodies associated with a herpes-like virus (Photo: J. Frank Morado, National Marine Fisheries Service, Seattle)



TEM of herpes-like virus particles (arrow) associated with intranuclear inclusions in antennal gland epithelium of blue king crab (Photo: J. Frank Morado, National Marine Fisheries Service, Seattle)

Prokaryotic Intracytoplasmic Inclusions

I. Causative Agent and Disease

Unlike bivalve molluscs, there are fewer reports of prokaryotic intracytoplasmic inclusion bodies in crustaceans of which 13 cases were caused by rickettsia-like organisms and one other by chlamydia-like bacteria. All infections produced intracytoplasmic inclusions or microcolonies infecting a wide range of tissues in both freshwater and marine crustaceans. The organisms are either confined to the hepatopancreatic epithelium or are systemic and vary in their significance from mildly to seriously pathogenic causing cell enlargement with organ and tissue necrosis including demonstrated or suspected mortality. However, in several of these cases other serious pathogens were also present which may have contributed to the mortality and the observed disease syndrome.

II. Host Species

The single documented chlamydia-like agent was reported from a large Dungeness crab mortality in Puget Sound, Washington. Rickettsia-like agents have been reported from crustaceans in the United States from Florida, Hawaii and Washington, and from British Columbia, Canada, France, Sweden, Mexico, Ecuador, Madagascar, China, Malaysia and Australia. Host species have included wild freshwater amphipods and cultured crayfish, at least five wild and cultured species of penaeid shrimp, one species of wild pandalid shrimp, and one cultured and three wild crab species including a 1984 report of one blue king crab from the eastern Bering Sea near St. Lawrence Island. Later studies (1990) in southeast

Alaska reported a similar rickettsial agent infecting one blue and one golden king crab held captive after collection from Glacier Bay and Lynn Canal near Haines, Alaska.

III. Clinical Signs

Clinical signs vary from normal in appearance to lethargy with mortality and tissue discolorations. King crabs infected by rickettsial organisms may have arrested ovarian development, become lethargic and die when held for prolonged periods of time. Infected tissues in king crabs have included the epithelial cells of the antennal gland and hepatopancreas that become indurated and friable. Histological examination of infected tissues demonstrates enlarged cells with intracytoplasmic inclusions composed of microcolonies of rod-shaped bacteria causing disseminated granulomatous foci and caseous necrosis of the tissues.

IV. Transmission

Certain rickettsia-like organisms in cultured and wild shrimp have been transmitted horizontally by cannibalism and via seawater exposure. Similar studies with other rickettsias either have not been successful or the mode of transmission is unknown.

V. Diagnosis

Histological examination of infected tissues reveal the typical enlarged cells containing microcolonies of organisms. Confirmation of typical rickettsial or chlamydial morphology is by transmission electron microscopy. PCR may be available for certain agents described in the literature. None of these agents have

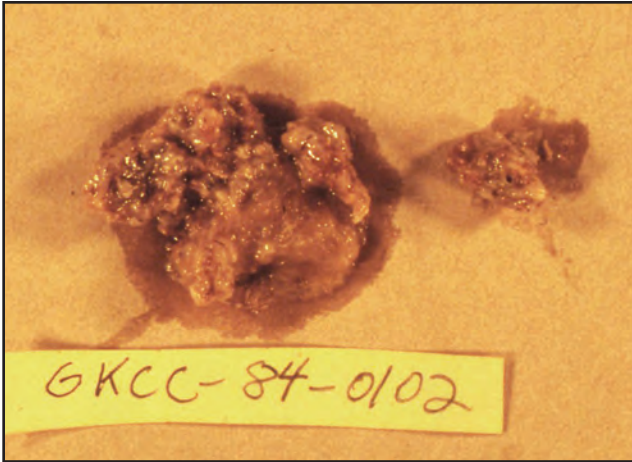
been isolated in culture using conventional methods.

VI. Prognosis for Host

Infections can be light and insignificant but low to high mortality has also been reported for both wild and cultured shrimp and crabs.

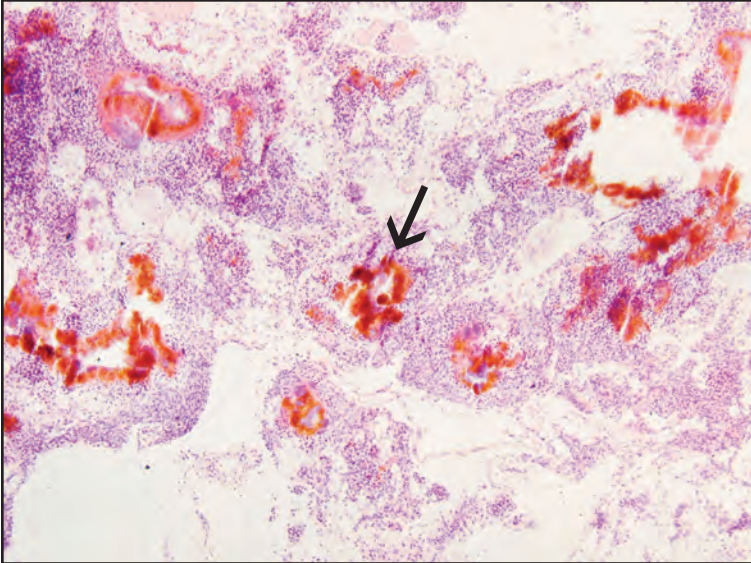
VII. Human Health Significance

There are no known zoonotic human health concerns regarding infection of crustaceans by these poikilothermic organisms which are different from similar organisms causing diseases in higher animals.

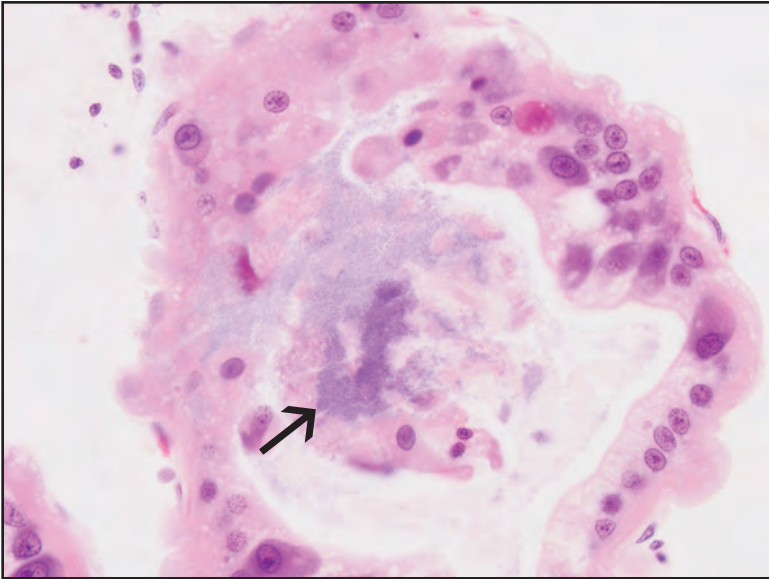


Caseous necrosis of hepatopancreas from golden king crab infected with a rickettsia-like organism that has destroyed hepatopancreatic tubules

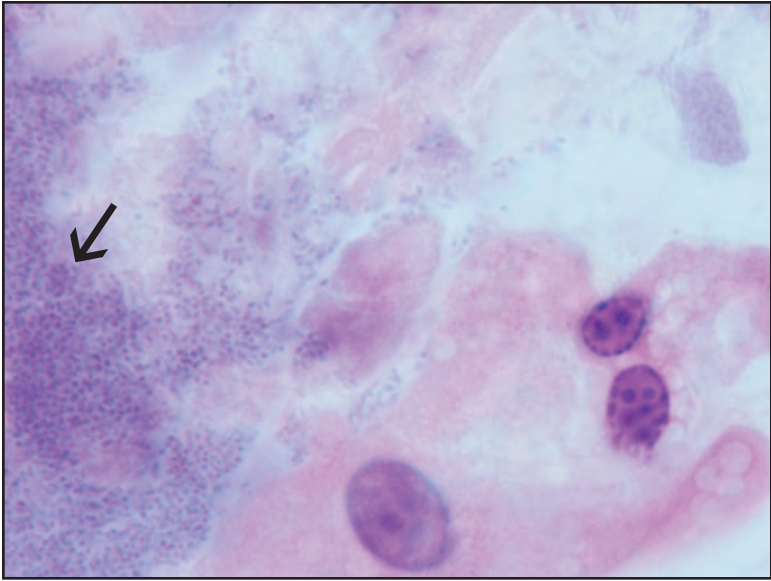
Prokaryotic Intracytoplasmic Inclusions



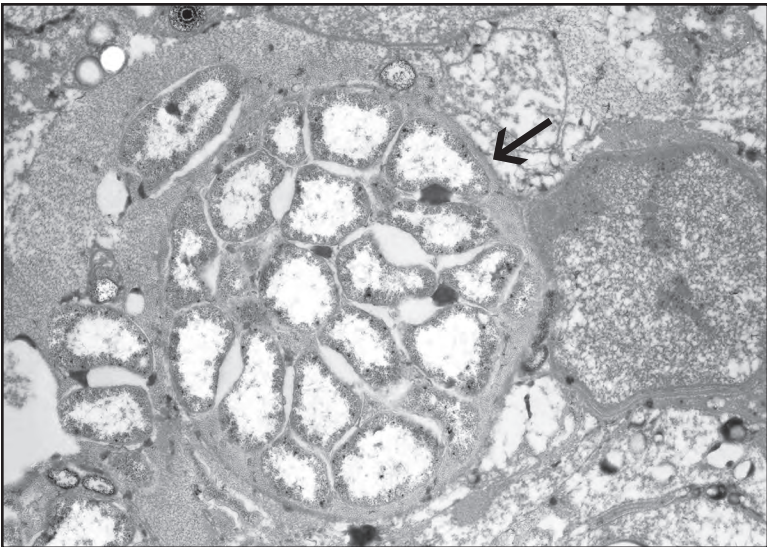
Histological section of tubular necrosis (arrow) and intense host inflammatory infiltration caused by infection with rickettsia-like organisms



Histological section of infected hepatopancreas epithelium showing microcolonies (arrow) of rickettsia-like organisms



Higher magnification of rickettsia-like organisms (arrow)



TEM of an infected hepatopancreatic cell showing a colony of rickettsia-like organisms (arrow)

Shell Disease

I. Causative Agent and Disease

Shell disease is a progressive degradation of the crustacean cuticle characterized externally by melanized brown to black focal lesions of varying size and severity regarding penetration of the surface exoskeleton. The disease can occur in nearly all freshwater and marine crustaceans, usually at low prevalences except when host animals are stressed by poor environmental conditions caused by intensive aquaculture, animal impoundment or waters polluted by chemicals, sewage or heavy metals. The shell erosion is largely attributed to colonization by chitinoclastic bacteria in areas of shell injury initially caused by poor environmental conditions, predation or cannibalism. Studies of shell disease in some crab species have shown that resulting shell ulcerations lead to limited septicemia by these and other opportunistic bacteria resulting in damage to internal organs and tissues. Many different bacteria have been associated with shell disease but common isolates include species from several Gram-negative genera such as *Achromobacter*, *Acinetobacter*, *Aeromonas*, *Plesiomonas*, *Pseudomonas* and *Vibrio*, all of which are commonly found on the shell surface of healthy animals. Fungal organisms are rarely encountered in the larger more severe lesions.

II. Host Species

Shell disease has been reported to occur in many different species of crustaceans worldwide. In Alaska, shell disease has been observed in feral populations of red, blue and golden king crabs, Tanner crabs and Dungeness crabs. However, all freshwater and marine crustaceans are considered susceptible to the disease.

III. Clinical Signs

Crustaceans with shell disease present with brown to black focal shell erosions of varying size and severity that may penetrate into the soft tissues.

IV. Transmission

Transmission is horizontal via water containing the common flora of chitinoclastic bacteria. Initiation of the external lesions generally requires previous shell injury or degradation as a portal of bacterial invasion. In Alaska, shell disease, loss of limbs, lower fecundity and mortality in Dungeness crabs have been associated with benthic deposits of decomposing bark and sulfide at logging transfer sites.

V. Diagnosis

Diagnosis is determined by typical shell surface lesions associated with Gram-negative bacterial rods that can be cultured on conventional media and identified by biochemical tests. Histological examination indicates varying degrees of melanization, erosion and ulceration of the shell layers with bacteria and occasional protists colonizing the surface accompanied by inflammatory exudate in the underlying dermis and epidermis. Hemocytes may form a protective pseudomembrane overlying some lesions.

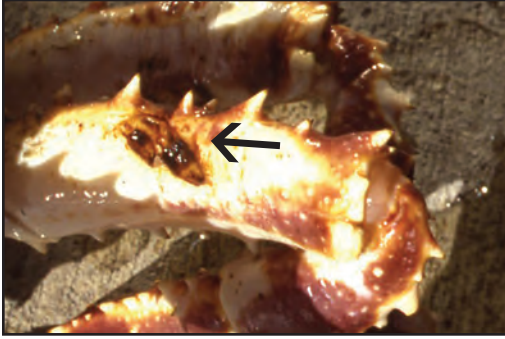VI. Prognosis for Host

In the initial stages, shell disease is likely not fatal but mortality is known to occur from adhesion of molted shells at the lesion sites leading to incomplete withdrawal from the old exoskeleton. Mortality can also occur from secondary bacterial septicemia if shell erosion progresses to the soft underlying tissues.

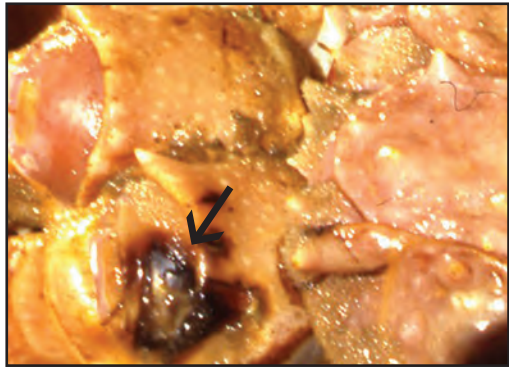
VII. Human Health Significance

Shell disease in crustaceans is unsightly and some of the associated vibrios and pseudomonad bacteria are known human pathogens. However, there

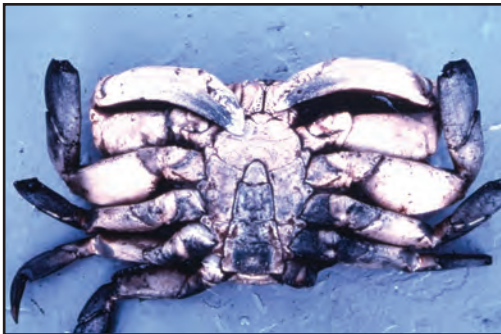have been no reports on which to base any zoonotic human health concerns associated with shell disease in crustaceans.



Erosion of carapace (arrow) due to shell disease in red king crab



Erosion of carapace (arrow) due to shell disease in golden king crab



Dungeness crab from a logging transfer site with shell disease and loss of limbs (Photo: C. E. O'Clair, National Marine Fisheries Service, Juneau)

Black Mat Syndrome

I. Causative Agent and Disease

Trichomaris invadens, the causative agent of Black Mat Syndrome, is a chitinoclastic, obligate Ascomycete fungal parasite of Tanner crabs. The fungus proliferates on the surface of the exoskeleton invading the shell and internal soft tissues causing destruction with little or no host response. Infected crabs have varying degrees of a dense black tarry encrustation on the surfaces of the carapace and appendages.

II. Host Species

In the 1970's and early 1980's, the fungus was prevalent in the Alaskan Tanner crab fishery around Kodiak Island and in the northwestern Gulf of Alaska, primarily infecting *Chionoecetes bairdi* at prevalences as high as 75%. The fungus rarely has been found infecting *C. opilio* and *C. tanneri* but has also been reported in *C. bairdi* from deep fiords in northern British Columbia, Canada.

III. Clinical Signs

Infected crabs have varying degrees of encrusting nodules or pustules forming a dense, hard, black, tar-like covering over parts of the exoskeleton. Histological examination of internal soft tissues shows dense proliferation of non-pigmented fungal hyphae and tissue necrosis. There is a significant increase in the percentage of eosinophilic granulocytes in circulating hemolymph of infected crabs while infected female crabs may be barren.

IV. Transmission

The mode of transmission is unknown but is likely horizontal via infectious ascospores in ambient seawater or

by direct contact with infected crabs.

V. Diagnosis

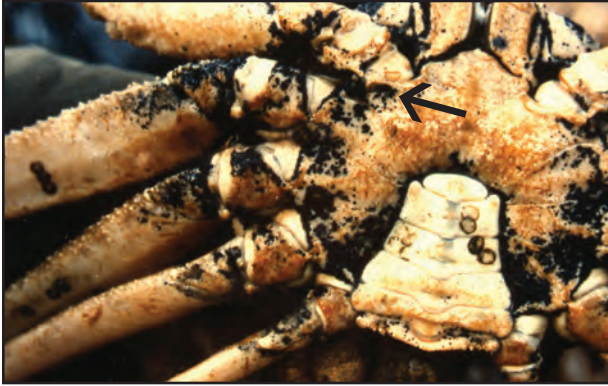Varying degrees of a black encrusting fungal mat on the exoskeleton of Tanner crabs is confirmed as *Trichomaris invadens* by wet mounts or histological examination showing the external thick-walled, black pigmented, infrequently septated hyphae with fruiting bodies or perithecia containing many asci each of which contains eight ascospores. Each ascospore has a long thin filament tightly wound around each end that unwinds when the spore is discharged. Internal tissues are invaded by dense proliferations of non-pigmented hyphae also having infrequent septa. Internal fungal hyphae are positive (black) when stained by Grocott's methenamine-silver method for fungi. The fungus has not been cultured successfully on artificial media.

VI. Prognosis for Host

Moderate fungal infection likely prevents molting and causes blindness if eyestalks are invaded. Severe infections likely result in crab mortality, however, the pathogenesis of the disease has not been studied in the laboratory. Black mat appears to occur more frequently in old shell or skip molted crabs. Infected sublegal-sized animals that fail to molt will not reach legal size and immature females will not reach sexual maturity.

VII. Human Health Significance

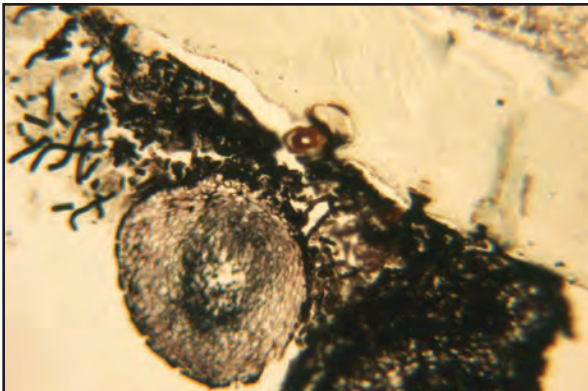
There are no known zoonotic human health concerns regarding consumption of Tanner crab meat infected with *Trichomaris invadens*.



Black mat fungus (arrow) infecting the underside of the carapace of a Tanner crab



Severe black mat fungus infection of the dorsal carapace in each of two Tanner crabs (Photo: J. Frank Morado, National Marine Fisheries Service, Seattle)



GMS stain of black mat fungal hyphae and fruiting body penetrating the shell surface of an eyestalk in Tanner crab (Photo: J. Frank Morado, National Marine Fisheries Service, Seattle)

Fungal Infection of Captive Red King Crabs

I. Causative Agent and Disease

An unidentified marine fungus caused mortality of four captive adult red king crabs producing a disease characterized by carapace discoloration of the walking legs and multiple granulomas and necrosis in the underlying epidermal and sub-epidermal tissues. There are no other known reports in the literature of a similar fungus infection in adult red king crabs. Whether the fungus infection occurs in wild crabs or is related to the stress and environment of captivity is not known.

II. Host Species

The fungus occurred in captive adult red king crabs collected from Cook Inlet, Alaska, but other crab species may be susceptible.

III. Clinical Signs

Focal yellow-brown discoloration appears on the carapace of walking legs followed by deep necrotic ulceration of the underlying soft tissues, loss of affected legs and crab mortality. The lesions are localized and not systemic characterized histologically by severe hemocyte infiltration and granulomas forming around fungal hyphae.

IV. Transmission

The mode of transmission is unknown but assumed to be horizontal within the water column, probably requiring an injury to the carapace as a portal of entry.

V. Diagnosis

Diagnosis is by observation of typical focal discolorations of the carapace (see similar lesions in shell disease section) followed with histological confir-

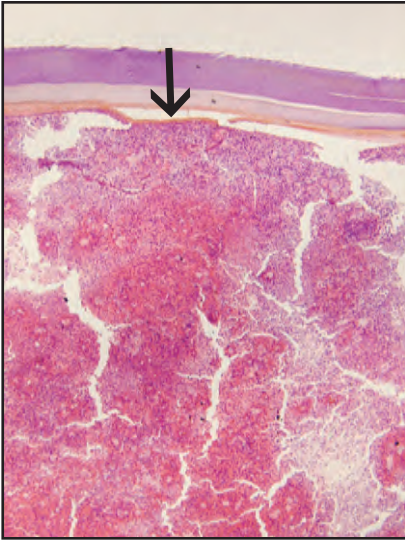
mation of granuloma formation around branching aseptate fungal hyphae that are positive (black) when stained with Grocott's method of methenamine-silver nitrate (GMS) for fungi. An opportunity for further characterization of the fungus by attempted isolation on artificial media has not occurred.

VI. Prognosis for Host

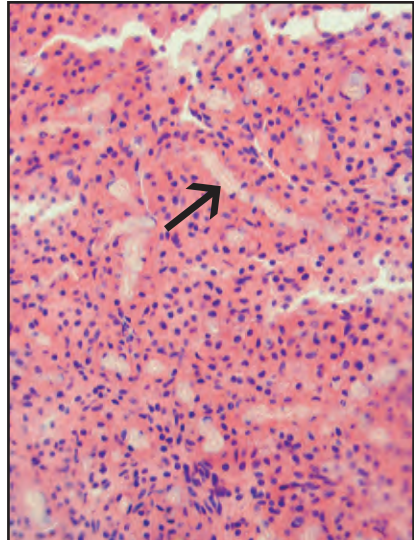
This fungal infection of the carapace results in deep localized invasion of underlying soft tissues, secondary bacterial infection, leg loss and crab mortality. Even minor shell damage may result in adhesion of the old carapace to the site of the wound during molting causing incomplete ecdysis and mortality of the crab. Whether this fungus occurs in wild populations of king crabs or is an artifact of captivity is not known.

VII. Human Health Significance

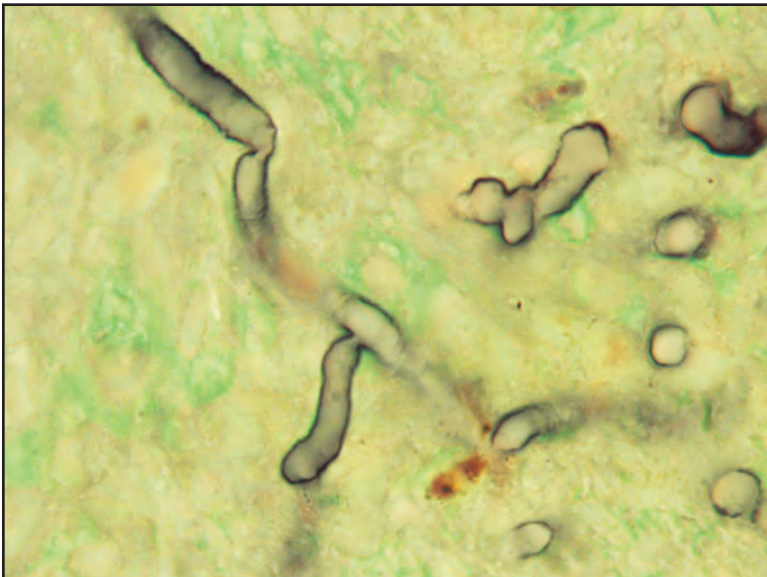
Although unsightly, this fungal infection of captive red king crabs is unlikely to have any zoonotic significance for human health.



Histological section of fungal hyphae within localized granuloma (arrow) in soft tissues beneath the carapace of infected red king crab



Higher magnification of granuloma and fungal hyphae (arrow)



GMS stain of aseptate fungal hyphae (black) from figures above

Haplosporidian-like Parasite of Shrimp

I. *Causative Agent and Disease*

Haplosporidian protozoa are within the phylum Haplosporidia, class Haplosporea within the order Haplosporida in the family Haplosporidiidae. Reports of haplosporidians in crustaceans are few and, although they have potential as serious pathogens, their prevalences have been low and distributions rare. An unidentified haplosporidian-like protozoan, previously described as dinoflagellate-like, occurs in spot and pink shrimp where unconfirmed prevalences of 10-50% have been reported. However, documented prevalences have been less than 1% but parasitized prawns did not survive in captivity. Uninucleate stages of the parasite replace hemocytes in the hemal sinuses and multinucleated plasmodial forms occur in tissues causing systemic disease.

II. *Host Species*

This haplosporidian-like parasite has been reported in spot and pink shrimp from the Strait of Georgia in British Columbia, Canada and from Yakutat and Prince William Sound in Alaska.

III. *Clinical Signs*

Parasitized shrimp are lethargic, have an unusual red color with chalky white musculature and characteristic cloudy or milky hemolymph containing myriad numbers of the parasite.

IV. *Transmission*

The mode of transmission is unknown.

V. *Diagnosis*

Wet mounts and stained smears of tissue exudate and hemolymph demonstrate a circular non-motile protozoan

of about 14-20 μm in diameter with a single central nucleus having a distinct outline and no dinokaryotic figures. This nuclear profile distinguishes the parasite from the *Hematodinium* dinoflagellate in Tanner crabs (discussed elsewhere). Histological examination demonstrates the uninucleate form observed systematically within the hemal sinuses and a larger multinucleated plasmodial form within the tissues. Transmission electron microscopy of nuclear detail further demonstrates less condensed nuclear chromatin that does not cause irregular bulging of the well-defined nuclear envelope. These features produce a distinct nuclear profile. Various other ultrastructural features distinguish this parasite from the Tanner crab *Hematodinium* sp.

VI. *Prognosis for Host*

This haplosporidian-like protozoan causes mortality in parasitized shrimp by displacement of hemocytes and normal organ tissues. However, the actual population prevalence may be quite low with insignificant mortality.

VII. *Human Health Significance*

There are no apparent zoonotic human health concerns with the presence of this haplosporidian-like parasite in shrimp. However, the meats of parasitized shrimp may be unsuitable in texture for human consumption.

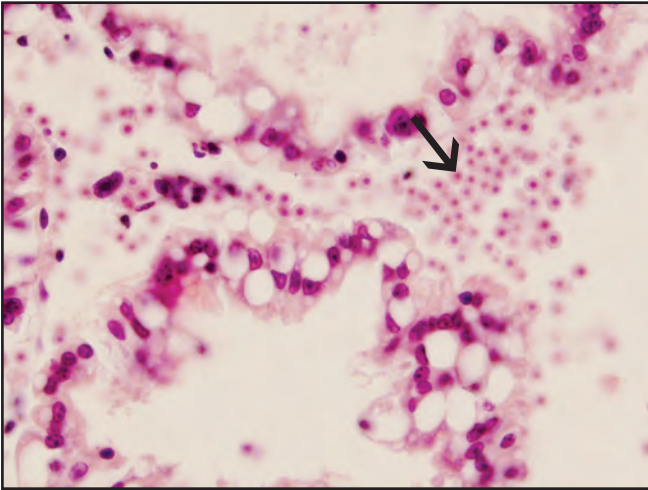


Red "cooked" appearance of spot shrimp parasitized by a haplosporidian-like protozoan

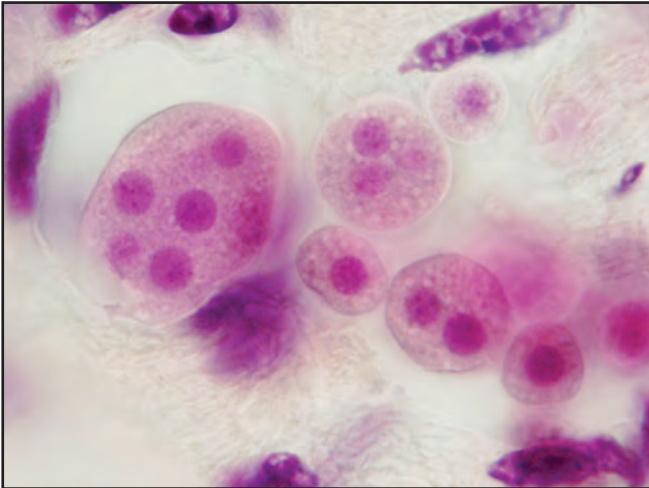


Smear of mucinous milky tissue exudate containing myriad numbers of organisms

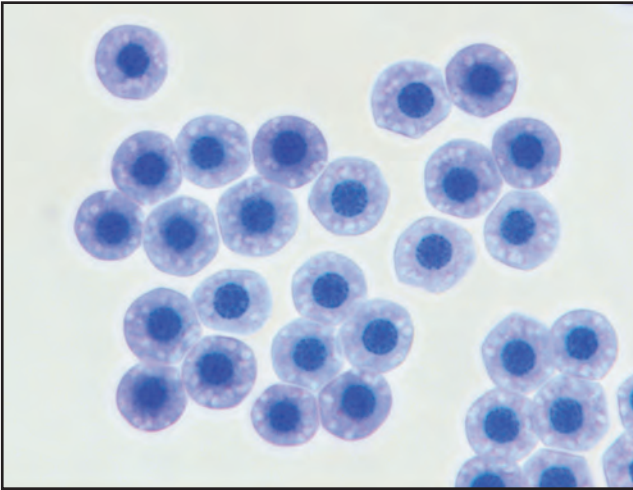
Haplosporidian-like Parasite of Shrimp



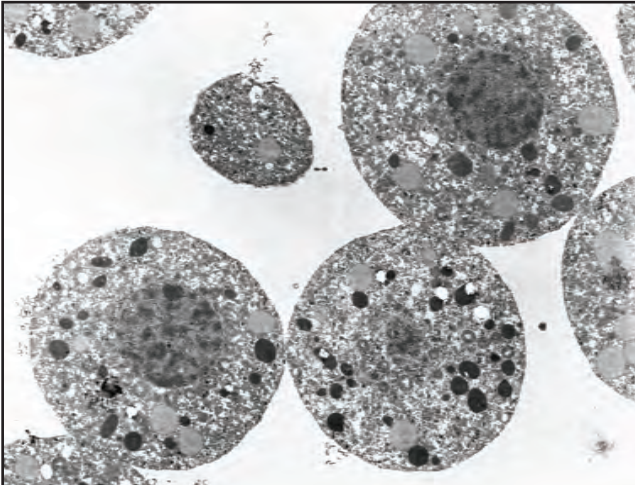
Histological section of a haplosporidian-like parasite (arrow) in the hepatopancreas of spot shrimp



A higher magnification of multinucleated plasmodial forms in histological section



A stained smear of fixed uninucleate forms of the parasite



Ultrastructural detail of the parasite showing less condensed nuclear chromatin and a well defined nuclear profile

Hematodinium sp. - Bitter Crab Disease of Tanner Crabs

I. Causative Agent and Disease

Bitter crab disease is caused by a parasitic dinoflagellate, *Hematodinium* sp. belonging to the protozoan phylum Alveolata, subphylum Dinoflagellida, order Syndinida and family Syndiniceae. A major feature of classification for dinoflagellates is the biflagellated grooved dinospore stage. Obligate *Hematodinium* parasites have been described from several species of crustaceans, certain fishes and cephalopods. In crustaceans the type species is *H. perezi* parasitizing the European shore crab. All *Hematodinium* described from crustaceans parasitize the hemolymph causing systemic disease and mortality affecting at least 26 species of crustacean hosts in Europe, Australia and North America including many commercially important crab species and 13 species of benthic amphipods.

II. Host Species

The bitter crab *Hematodinium* is reported from Tanner and snow crabs (*C. bairdi*, *C. opilio*) in southeast Alaska, the Gulf of Alaska and the eastern and western Bering Sea; from deep water Tanner crabs (*C. tanneri*) in British Columbia, Canada and from snow crabs in Atlantic Canada.

III. Clinical Signs

Parasitized crabs are lethargic and die when handled, have an exaggerated red color of the carapace, flaccid chalky textured meat and white opaque hemolymph caused by the myriad numbers of dinoflagellates. The cooked meats of parasitized crabs have an astringent aspirin aftertaste and are unmarketable, hence the "bitter crab" name of the disease.

IV. Transmission

Although the natural route of transmission has not been established, there are likely to be several modes in which the parasite is transmitted horizontally via: stages of the parasite in seawater that enter breaks in the cuticle during mating and molting; cannibalism or feeding on detritis containing resting spores; sexual transmission via seminal fluids of parasitized male crabs and possibly through a reservoir host such as bottom dwelling amphipods. The parasite and disease have been transmitted in the laboratory by injection of hemolymph containing vegetative trophonts and dinospore stages. Life history stages include: trophonts which are single cells and have slow division; larger plasmodia with multiple nuclei; pre-spores with multiple nuclei and rapid division followed by sporulation of biflagellated spores with a single nucleus. Spores are of two types, a large macrospore and a small microspore, generally with only one spore type occurring per host. Spores may possibly have a disseminatory or resting stage function rather than transmission. Laboratory studies suggest that the life cycle of the parasite occurs over a 15 to 18 month period. Infestation likely occurs from the trophont stage during the spring molting period from mid-March to May. Crabs dying in the summer and fall following sporulation were likely parasitized in the spring of the previous year. After sporulation in the fall the prevalence of parasitism becomes almost undetectable (eclipse) until the new infestations of the previous spring build to detectable levels that can be observed the following late winter and early spring.

V. *Diagnosis*

Diagnosis is based on typical clinical signs with the occurrence of myriad numbers of dinoflagellate stages (usually non-motile trophonts) in wet mounts or stained smears of hemolymph. Trophonts are 15.4 X 20.7 μm , have an indistinct nuclear profile and foamy cytoplasm with droplets exuding from the surface pellicle in a stained hemolymph smear. A key diagnostic feature visible in many trophonts is the dinokaryon nuclear division producing condensed V-shaped pairs of chromosomes. Nonmotile plasmodia are similar in appearance but larger and multinucleated. Prespores are similar to plasmodia but each nucleus has a distinct lobed nuclear outline. Macrospores are oval 15.2 X 11.4 μm having slow motility and a beaked protrusion on one end. The nucleus is longer than it is wide with a distinct outline. The microspore is elliptical and smaller at 12.0 X 4.4 μm and has rapid motility with a refractile body at the posterior end and 2 flagella more often visible on stained smears. The microspore develops an obvious bent corkscrew shape within 6 days after sporulation. Histological examination demonstrates parasite stages within hemal sinuses throughout the tissues of the crab host. PCR primers are available for certain *Hematodinium* sp. parasitizing commercial crab species.

VI. *Prognosis for Host*

Virtually 100% mortality occurs in Tanner crabs naturally parasitized by *Hematodinium* sp. when maintained in the laboratory. A similar mortality of parasitized crabs is assumed to occur in wild Tanner crab populations. Significantly higher prevalences of bitter crab disease occur in new shell crabs and crabs less than 60 mm carapace width. There is a seasonal prevalence/intensity peaking in July through October fol-

lowed by a reduction or eclipse until late winter and early spring. Peak mortality occurs in August through September due to sporulation. Chronic mortality occurs in weakened hosts from secondary infections by other pathogens. Options for control of bitter crab disease in southeast Alaska include: harvest Tanner crabs from October through November during the eclipse period of the disease when crab meats may be less full but of acceptable quality (requires no culling of parasitized crabs); grossly parasitized crabs should be properly disposed of (landfill; incinerated; ground and cooked or chlorinated) rather than released; discourage culling through education programs to recognize the disease and follow proper disposal; provide an economic incentive by developing alternative use products for harvested parasitized crabs (surimi, chitin products, etc.).


VII. *Human Health Significance*

There are no zoonotic human health concerns regarding bitter crab disease in Tanner crabs. However, parasitized crabs have an unpalatable flavor and undesirable meat texture.

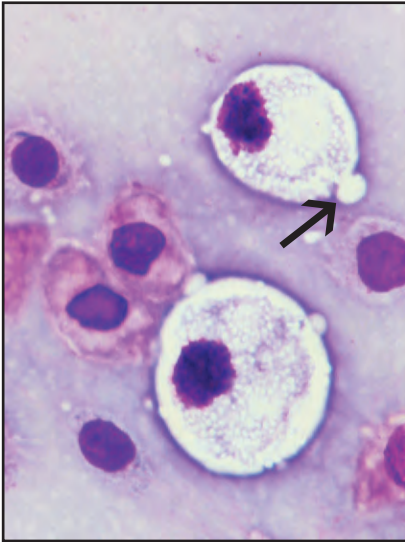
Hematodinium sp. - Bitter Crab Disease of Tanner Crabs



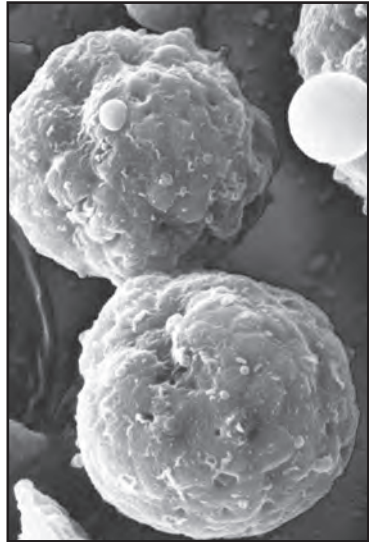
Exaggerated reddening of the crab carapace (bottom) typical of bitter crab disease



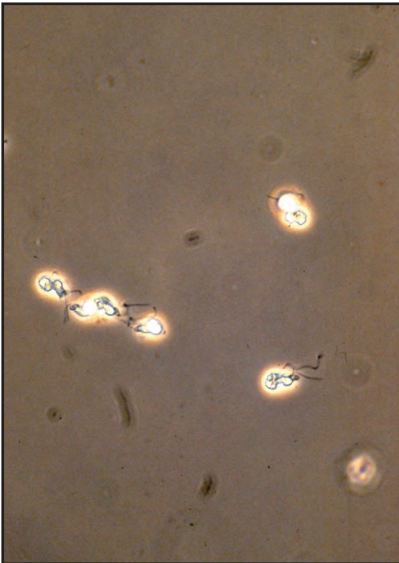
White viscera with milky hemolymph (arrow)



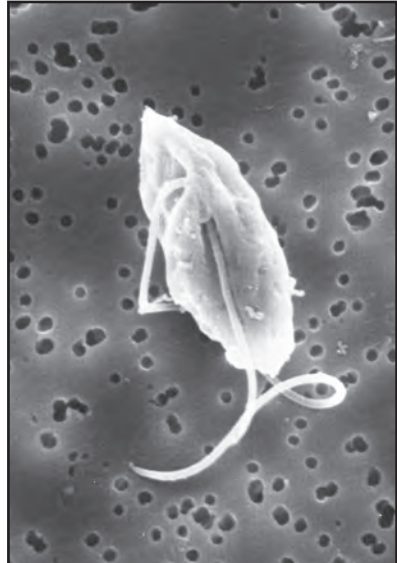Vegetative stages in a hemolymph smear with irregular nuclear profile and droplets (arrow) exuding from pellicle



SEM showing droplet exuding from pellicle of vegetative stage

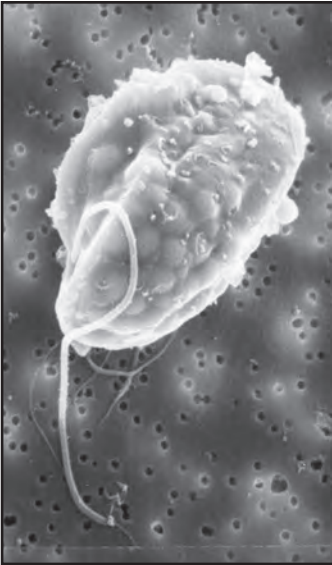

Twisted microspores with flagella visible in phase contrast microscopy

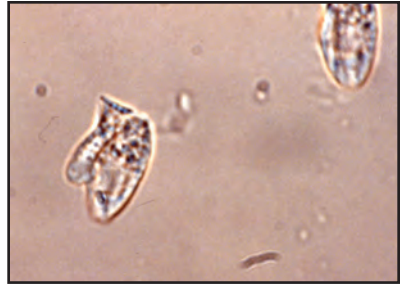

SEM showing the smooth surface of a microspore and two flagella

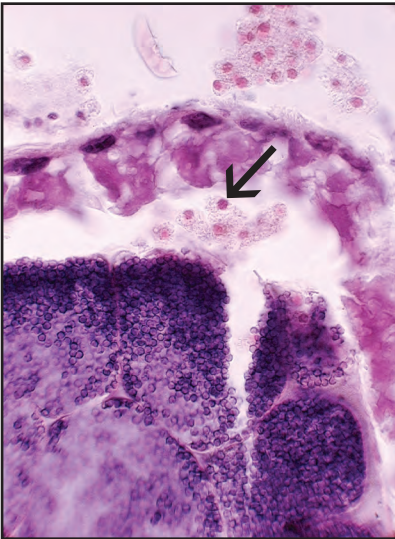
Hematodinium sp. - Bitter Crab Disease of Tanner Crabs



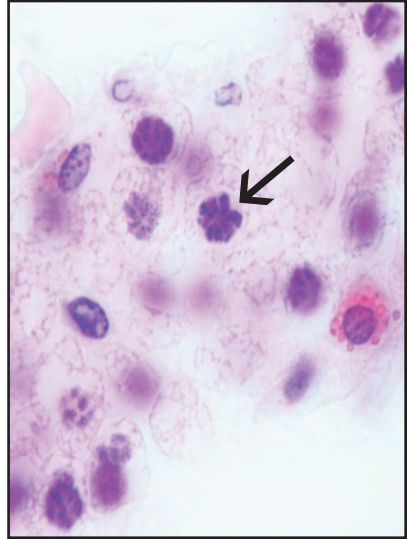
Beaked macrospore (SEM) showing warty surface and one of the two flagella



Wet mount of beaked macrospores

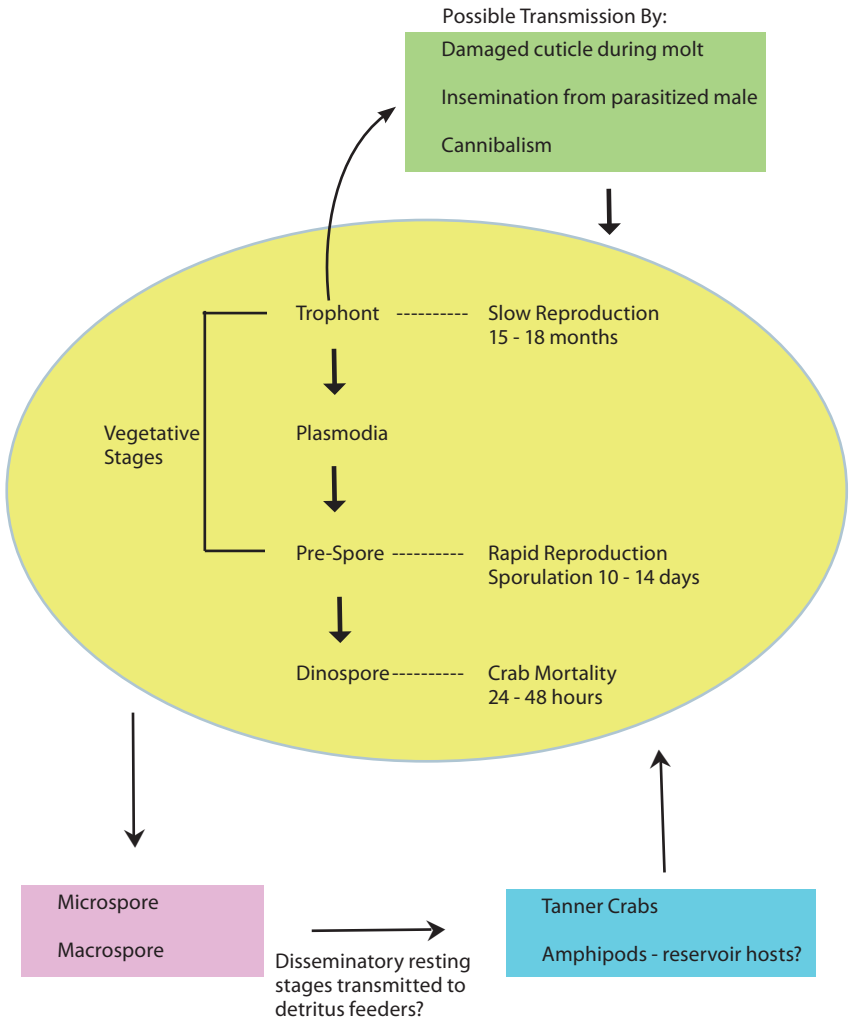


Histological section showing vegetative stages (arrow) inside spermatophore



Histological section showing typical dinokaryon nuclear division (arrow)

Possible *Hematodinium* Life Cycle



Hematodinium-like Disease of Dungeness Crabs

I. *Causative Agent and Disease*

Obligate parasitic dinoflagellates that belong to the genus *Hematodinium* sp. are in the protozoan phylum Alveolata, subphylum Dinoflagellida, order Syndinida and family Syndiniceae. A major feature of classification for all dinoflagellates is the biflagellated grooved dinospore stage. *Hematodinium* parasites have been described from several species of crustaceans, certain fishes and cephalopods. In crustaceans the type species is *H. perezii* parasitizing the European shore crab. All *Hematodinium* described from crustaceans parasitize the hemolymph causing systemic disease and mortality affecting at least 26 species of crustacean hosts in Europe, Australia and North America including many commercially important crab species and 13 species of benthic amphipods.

II. *Host Species*

A *Hematodinium*-like parasite was observed in a single captive subadult Dungeness crab collected from the waters of Kodiak Island, Alaska in mid-May of 2003. It is the only known case of dinoflagellate parasitism in the Dungeness crab on record in the Pacific Northwest.

III. *Clinical Signs*

Clinical signs include lethargy followed by death associated with milky white hemolymph and grossly abnormal viscera characterized by pallid color and a white viscous exudate.

IV. *Transmission*

The mode of transmission is unknown but likely complex (see bitter crab disease section) involving several

developmental stages if confirmed to be *Hematodinium* sp.

V. *Diagnosis*

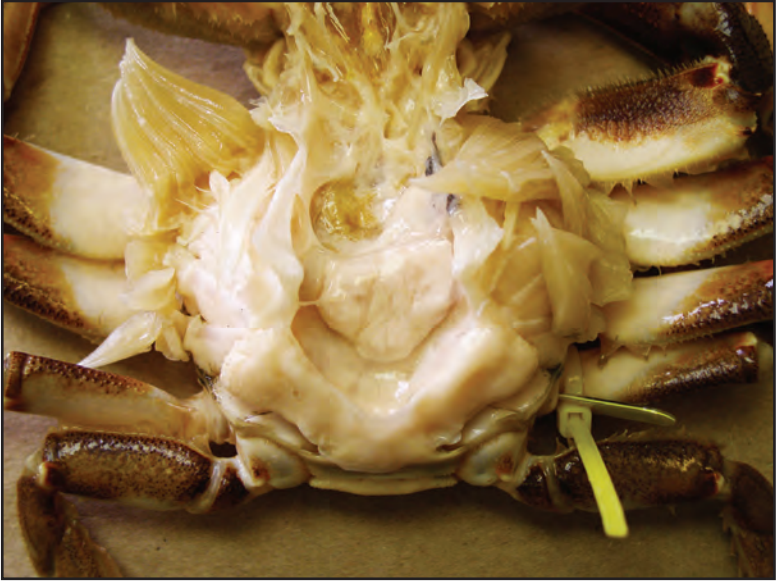Stained blood smears contain myriad numbers of apparent prespore stages, some of which have dinokaryon type condensed chromosomes in V-shaped configuration. Tissues were not available for further diagnostic analysis.

VI. *Prognosis for Host*

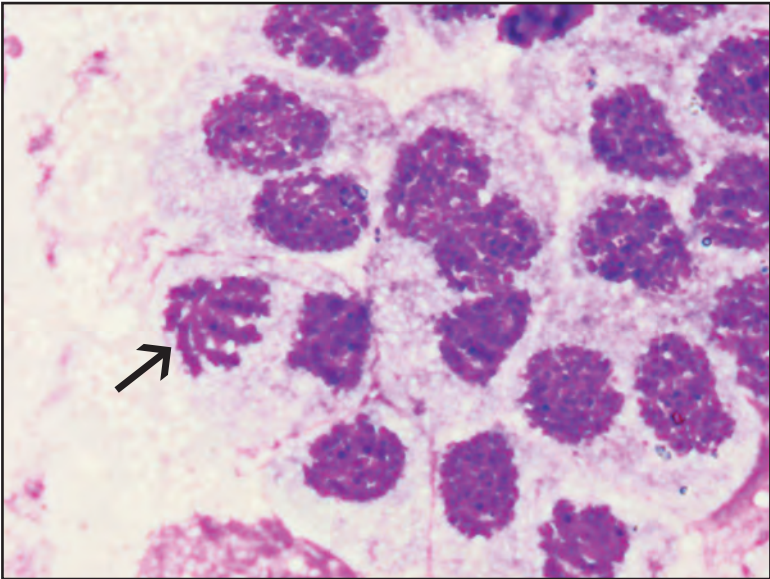
The single parasitized crab was one of several being held in crowded 10 foot circular tanks for a size at maturity study. Minor mortality, beginning in early July, occurred in the captive crab groups, some of which was due to stress-caused bacterial septicemia while other mortality was reportedly caused by this *Hematodinium*-like parasite.

VII. *Human Health Significance*

There are no zoonotic human health concerns regarding dinoflagellate parasitism in crabs. However, parasitized crabs often have an unpalatable flavor and undesirable meat texture.



Milky-white viscera and exudate of a Dungeness crab parasitized by a *Hematodinium*-like organism



Stained hemolymph smear of parasitized Dungeness crab showing *Hematodinium*-like prespores with dinokaryon type condensed chromosomes in V-shaped configuration (arrow)

Mesanophrys sp. Ciliate Disease

I. Causative Agent and Disease

Mesanophrys sp. (*pugettensis*) (syn *Anophrys*, *Paranophrys*) is a scuticociliate protozoan with holotrichous ciliation and a long trailing caudal cilium. These ciliates are primarily facultative pathogens of injured or captive crustaceans but have also been found in wild populations, most often in recently molted animals. Infestation is generally fatal causing a systemic disease with high mortality.

II. Host Species

Mesanophrys has a broad range with most reports occurring from several marine crab species in Europe and the Pacific Northwest. Closely related species have been reported in lobsters from Maine and Atlantic Canada and in cultured penaeid shrimp from China. In Alaska, *Mesanophrys* has been reported in wild isopods collected from Afognak Island and in captive blue and golden king crabs, Dungeness crabs and Tanner crabs from southeast.

III. Clinical Signs

Parasitized crustaceans are generally injured or otherwise stressed by captivity and exhibit lethargy, anorexia and ataxia followed by death. The hemolymph is cloudy or opaque from the presence of massive numbers of motile ciliates. Tissue pathology observed by histological examination is characterized by nearly complete destruction of peripheral and tissue hemocytes accompanied by massive tissue infiltration of the ciliates with severe systemic necrosis of major organs.

IV. Transmission

Transmission is horizontal from ambient seawater, usually requiring some

form of host debilitation or external injury as a portal of entry. The life cycle of this ciliate is simple and direct with reproduction by binary fission allowing parasite numbers to increase exponentially.

V. Diagnosis

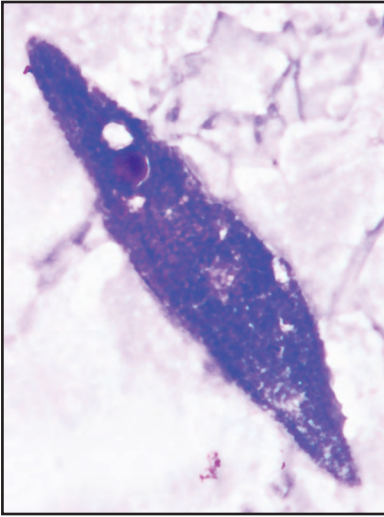
Diagnosis includes the typical gross clinical signs of injury, lethargy and mortality in conjunction with myriad numbers of elongate holotrichous ciliates each having a long trailing cilium in wet mounts of hemolymph and tissue smears. White focal areas of necrosis and coagulated hemolymph containing ciliates may also be observed on the surfaces of soft tissues (see bottom figure of blue king crab on page 111).

VI. Prognosis for Host

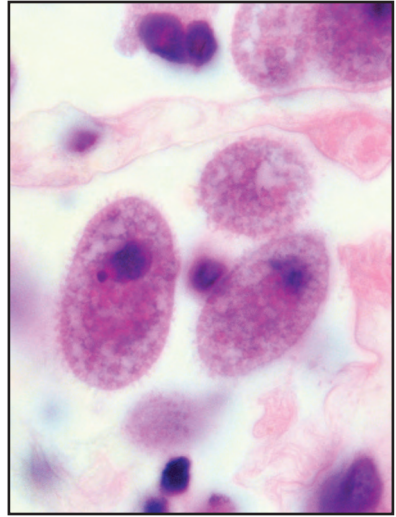
Mesanophrys generally causes high mortality in injured or captive crustaceans. Some measure of control for impounded animals may be achieved through improvement of environmental conditions and reducing crustacean densities to further reduce mechanical damage.

VII. Human Health Significance

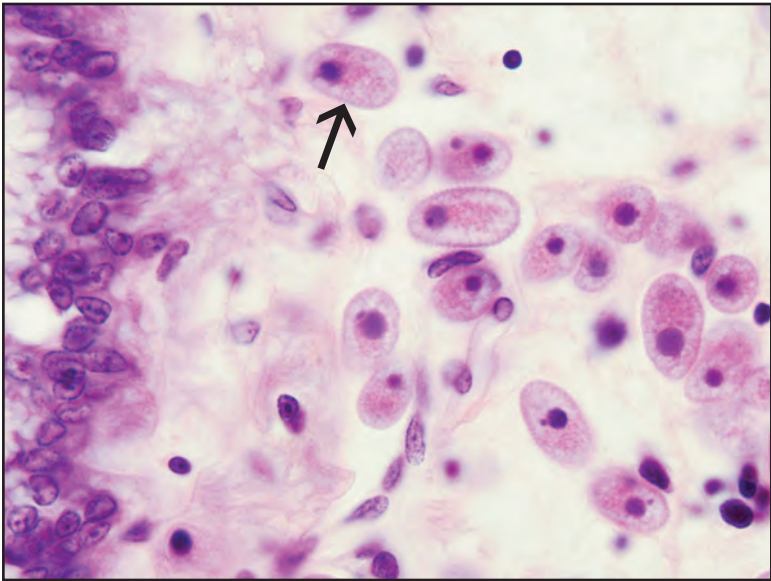
There are no zoonotic human health concerns regarding ciliate infestation of crustacean tissues.



Mesanophrys-like ciliate in hemolymph smear from parasitized Tanner crab



Higher magnification of *Mesanophrys*-like ciliates in histological section from blue king crab



Histological section of *Mesanophrys*-like ciliates (arrow) beneath the epidermis of a parasitized blue king crab

Thelohania and Other Microsporidia

I. Causative Agent and Disease

Microsporidia is a protozoan order within the class Microsporea within the phylum Microspora. However, there is controversial genetic evidence for a closer affinity to the kingdom of Fungi rather than Protozoa. All microsporidians are intracellular parasites that produce microspores (3 to 10 μm) as the infectious stage and complete their life cycles in a single host cell, generally with no alternate hosts. Microsporidia are one of the more common groups of parasites in crustaceans with over 140 species reported from all orders. Some microsporidians cause significant pathology, mostly affecting skeletal muscle. *Thelohania duorara* parasitizing pink, white and brown shrimps causes an opaque white abdomen typifying "cotton" or "milky" disease that destroys muscle and connective tissues. *Agmasoma penaei* also parasitizes shrimp causing destruction of many different tissues as well as parasitic castration. Two different undescribed species of *Thelohania* cause "cottage cheese" disease in both red and blue king crabs from Bristol Bay and the Bering Sea characterized by massive numbers of spores in all major visceral organs causing the tissues to appear white and curd-like. Another unidentified microsporidian in the family Nosematidae parasitizes mostly the musculature, including the heart, of golden king crabs while other unidentified microsporidians have been observed in the antennal gland of blue king crabs and in the body musculature of a single coonstriped shrimp from southeast Alaska.

II. Host Species

Microsporidia are ubiquitous and

have been reported parasitizing many different species of crabs, shrimps and other crustaceans in Europe, Thailand, Australia and on the Atlantic, Gulf and Pacific coasts of North America. In Alaska, microsporidia have been found in red, blue and golden king crabs from Bristol Bay and the Bering Sea and blue king crabs and coonstriped shrimp from southeast Alaska.

III. Clinical Signs

Clinical signs may include lethargy, mortality and tissues that are white or curd-like in appearance caused by tissue damage and replacement with the spores of the parasite. Shrimp often exhibit opaque white abdomens with a milky fluid exudate.

IV. Transmission

Transmission is horizontal when spores released from ruptured host cells are ingested by a suitable host. In the intestine of the new host each spore releases a hollow polar tube attaching the spore to a mucosal epithelial cell through which the internal amoeboid sporoplasm passes into the host cell cytoplasm. In some cases the parasite replicates in the host cell nucleus rather than in the cytoplasm. The sporoplasm may replicate in the intestinal cell or may be injected into a host phagocyte where it travels to other target tissues. In addition to transmission via the alimentary tract some species in amphipods may also be vertically transmitted to progeny from parasitized ova. Once in the target host cell the parasite undergoes further replication and development involving merogony producing plasmodia and meronts followed by sporogony producing sporonts that contain sporoblasts that mature into spores.

The entire process is complex and may have other intermediate stages depending on the species of microsporidian. Infected host cells and their nuclei also may respond by marked hypertrophy in which the enlarged cells become cysts or xenomas containing myriad numbers of the parasite.

V. *Diagnosis*

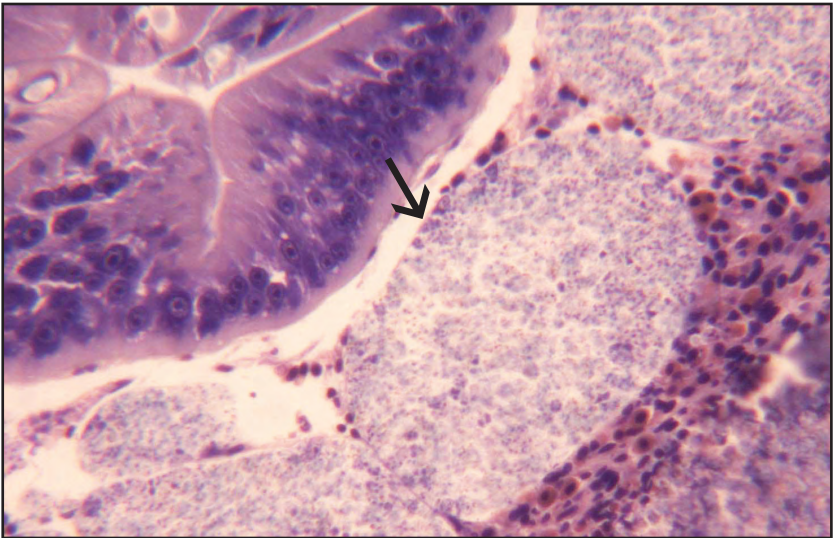
Stained and unstained hemolymph and/or tissue smears from parasitized animals generally demonstrate the microspores that can also be observed by histological examination. Major characteristics for classification of microsporidia are the size, shape and number of spores produced within sporonts. *Thelohania* has 8 spores each approximately 3 X 5 μm . DNA probes are available to identify some genera (*Agmasoma* sp.) of microsporidia.

VI. *Prognosis for Host*

Microsporidians in several crustacean hosts are serious pathogens causing significant mortality and/or debilitation resulting in predation or secondary pathogen infections. The prevalences of parasitism are generally low in most wild populations of crustaceans but can be very high in cultured shrimp. The king crab microsporidians are considered to be lethal parasites as well but have occurred at low prevalences (2-10%) that may not significantly impact king crab populations.

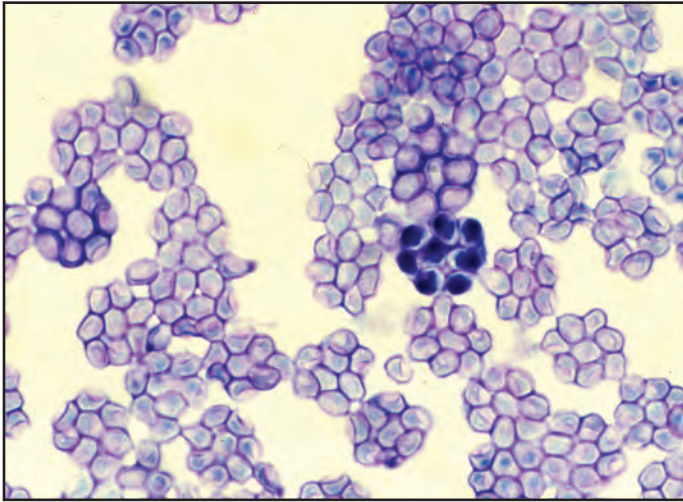
VII. *Human Health Significance*

Affected shrimp are generally unmarketable due to poor aesthetic quality. However, there are no zoonotic human health concerns regarding the parasitism of crustacean tissues by microsporidia.

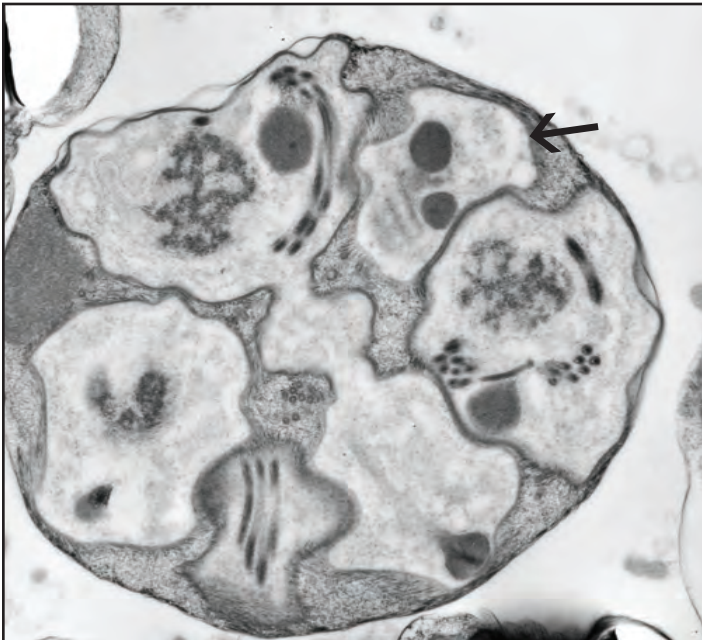


Histological section of *Thelohania* microspores (arrow) within digestive gland of red king crab (Photo: J. Frank Morado, National Marine Fisheries Service, Seattle)

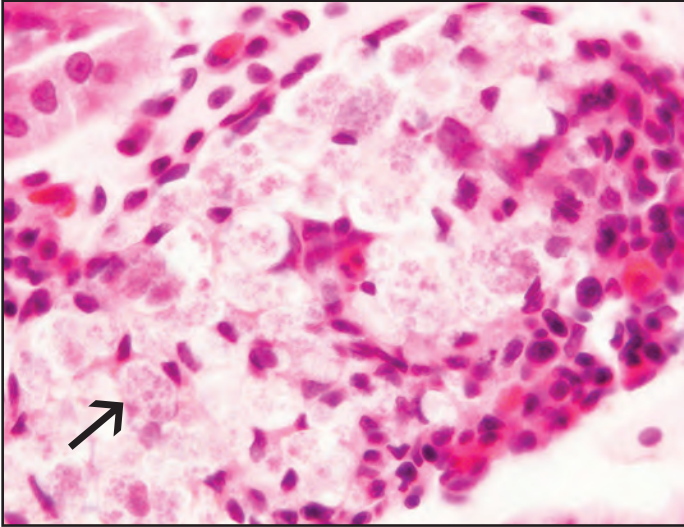
Thelohania and Other Microsporidia



Stained tissue smear showing packets of 8 spores typical of *Thelohania* sp.



TEM of spores (arrow) within sporont of *Thelohania* sp. (Photo: J. Frank Morado, National Marine Fisheries Service, Seattle)



Histological section of degenerating unidentified microsporidian spores (arrow) in the antennal gland of blue king crab

Carcinonemertes Egg Predator

I. Causative Agent and Disease

Worms belonging to the phylum Nemertea include the genus *Carcinonemertes* sp. in the family Carcinonemertidae. These nemerteans are specialized ectosymbionts that feed on the eggs of decapod crustaceans. Feeding is accomplished by puncturing the egg membrane with a knife-like stylet on the end of a proboscis that is everted with the foregut into the egg to ingest the contents. These egg predators can be major sources of egg mortality as demonstrated for several economically important decapod crustacean species. Egg predation was implicated in the collapse of the Dungeness crab fishery in southern California in 1960 and localized brood failure in the early 1980s for red king crabs in the Kodiak, Island and Cook Inlet areas of Alaska. At least six species of *Carcinonemertes* have been described from crabs; *C. carcinophila* (with 2 subspecies), *C. coei*, *C. epialti*, *C. errans*, *C. mitsukurii* and *C. regicides*. The effects of another nemertean egg predator, *Pseudocarcinonemertes homaris*, on the American lobster have been more difficult to quantify.

II. Host Species

Nemertean egg predators have been reported on many host species of crabs primarily in North America including commercially important species such as Dungeness crab, Tanner crab, red king crab, blue crab and the American lobster. The nemertean worm described from Alaska is *C. regicides* found on Tanner and red king crabs where significant egg predation/mortality in the latter host was implicated as causing previous localized population declines.

III. Clinical Signs

Clinical signs of infestation include dull pink to orange adult worms visible within the egg clutch, usually found on the funicular strands (stalks binding fascicles of setae) attaching the eggs to the pleopods of ovigerous female crabs. Empty or partially eaten eggs may be obvious in the egg mass where worms can be found inside when infestation is high. Juveniles may be present ensheathed in mucus on the uncalcified cuticle of the ventral surface of the host abdomen.

IV. Transmission

Variations occur depending on worm species but generally female *Carcinonemertes* are fertilized internally by entrance of waterborne male sperm through tegmental pores. The embryos are extruded through the gonoduct to hatch externally where the haplonemertean larvae undergo direct development into the juvenile stage during a planktonic existence. Juveniles settle out on crabs of any age or sex, produce a sheath of mucus and attach to various protected areas on the host exoskeleton. Attached worms apparently subsist by absorbing dissolved amino acids through the skin that leak from the crab arthrodiol membranes. When female crabs oviposit the resident worms migrate to the egg mass to feed and reproduce. Infested male crabs can transmit juvenile worms to female crabs during mating and transfer also occurs from the old to the new cuticle when a host crab molts.

V. Diagnosis

Diagnosis of *Carcinonemertes* infestation is determined by finding worms on the cuticle or in the egg mass of the host

crab and/or the presence of empty or partially eaten crab eggs. Species identification is based on morphological characteristics which, for *C. regicides*, include among others a smaller adult length of 1.0 mm, presence of an excretory system and a large anterior proboscis chamber or rynchocoelum.

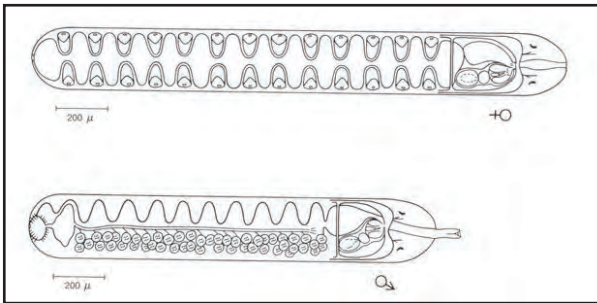
VI. Prognosis for Host

In ovigerous female crabs, heavy infestations of *Carcinonemertes* may cause extensive loss of eggs and subsequent

poor recruitment into the population if the prevalence of infestation is high. Epibiont fouling of egg masses may also result indirectly from worm feeding activity that produces a rich organic substrate from punctured eggs and worm feces.

VII. Human Health Significance

There are no zoonotic human health concerns regarding the presence of nemertean egg predators on decapod crustaceans.

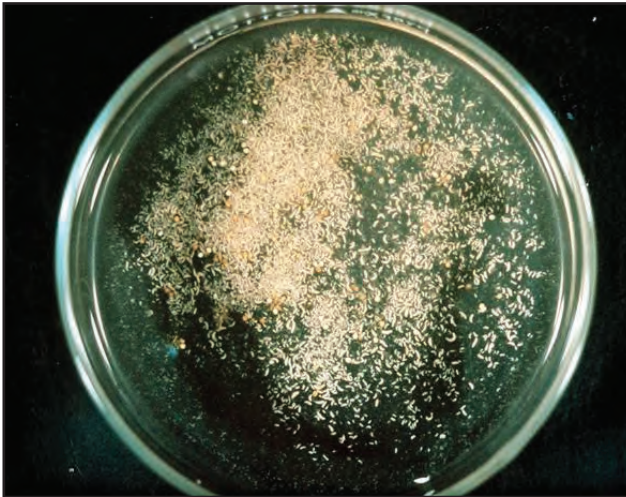


Drawing of *Carcinonemertes regicides* (J. Shields, Virginia Institute of Marine Science)

Carcinonemertes Egg Predator



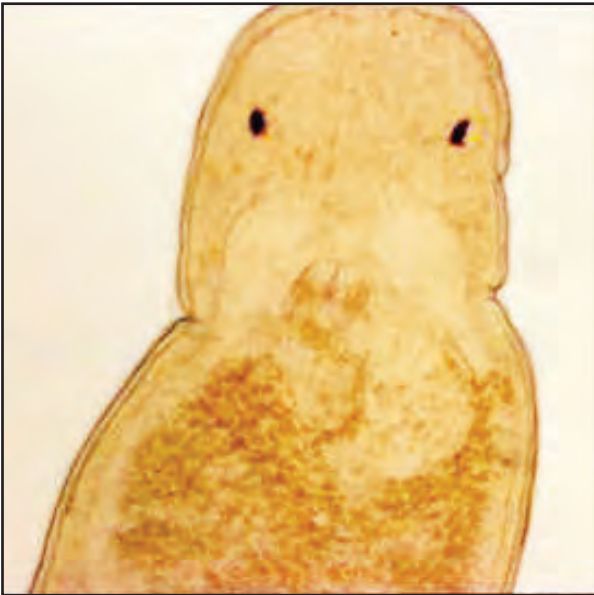Egg mass of a female red king crab infested by *Carcinonemertes* (Photo: J. Shields, Virginia Institute of Marine Science)



Carcinonemertes worms removed from egg mass above (Photo: J. Shields, Virginia Institute of Marine Science)



Higher magnification of king crab eggs infested by *Carcinonemertes regicides*
(Photo: J. Shields, Virginia Institute of Marine Science)



Higher magnification of single *Carcinonemertes regicides* worm
(Photo: J. Shields, Virginia Institute of Marine Science)

Crab Leech

I. Causative Agent and Disease

Leeches belong to the phylum Annelida (segmented worms) within the class Hirudinea consisting of over 500 species of freshwater, marine and terrestrial worms. They possess anterior and posterior suckers and a large number of leeches are not ectoparasitic. Common leeches in the North Pacific area include *Johanssonia arctica*, a parasite of several marine fish including cod and a vector for *Trypanosoma murmanensis*, a blood parasite of fish. Another leech, *Notostomum cyclostoma*, is parasitic on several fish species including cod, pollock, flatfishes, dogfish and skates and is a vector for the hemoflagellate fish parasite, *Cryptobia* sp. A smaller fish leech, *Malmiana* sp., is less common. Most notably, these leeches do not parasitize crabs but favor the carapace as a substrate for depositing eggs each in a single cocoon. The crustaceans function as transport hosts to disseminate the leeches and are unharmed.

II. Host Species

Several crab species may serve as transport hosts for the eggs of these leeches which are circumpolar in distribution. *Notostomum cyclostoma* occurs in the Seas of Japan and Okhotsk, the Bering Sea and along the Alaskan coast south to the Stikine River. In northern British Columbia, Canada it has been observed on golden and red king crabs and Tanner crabs in the Portland Inlet system. *Johanssonia arctica* has been reported in the Bering Sea and was likely transported into the Barents Sea with the introduction of red king crabs. In Alaska, adult leeches and cocoons, most likely *Notostomum cyclostoma*, have been observed on the shells of red, blue and golden king crabs, Tanner and snow

crabs and probably occur on the shells of other crab species as well.

III. Clinical Signs

Gross clinical signs include observation of attached adult leeches and/or closely adherent brown to black convex cocoons on the shell surfaces.

IV. Transmission

The leech eggs hatch on the shell surface of the crustacean and the juveniles find a fish host to parasitize and obtain a blood meal. Leeches are hermaphroditic, reproduce sexually and produce eggs. At some point a leech leaves its fish host to seek out a hard substrate, often a crustacean shell, on which to lay eggs. Each egg is encased in a single cocoon.

V. Diagnosis

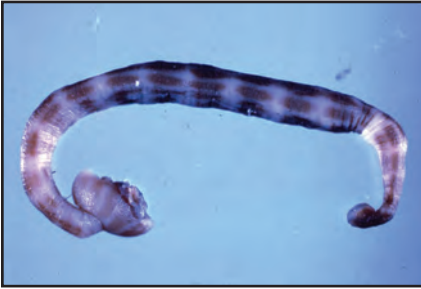Diagnosis is by visual observation of typical leech cocoons on the shell surface of various crustaceans, especially king and Tanner crabs. Attached adult leeches may also be present and can be identified by various morphological characteristics. Cocoons of *J. arctica* (1.5 mm X 1.0 mm) as well as adult worms (21.5 mm) are smaller than cocoons (7 mm X 5.5 mm) and adults (70 mm to 110 mm) of *N. cyclostoma*.

VI. Prognosis for Host

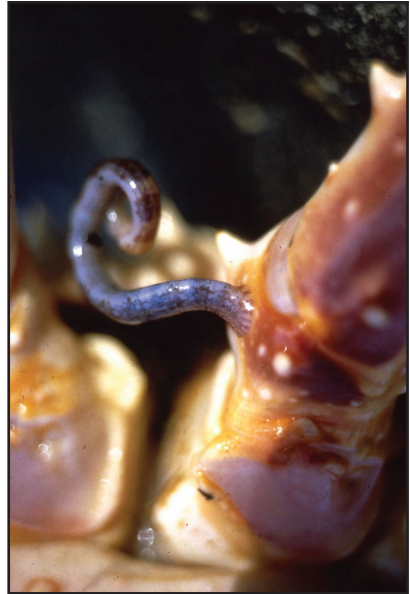There is no harm to the crustacean transport host caused by adult leeches or leech cocoons attached to the shell surfaces.

VII. Human Health Significance

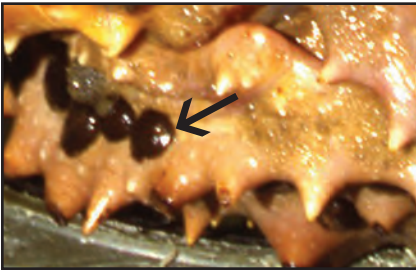There are no zoonotic human health concerns with the presence of leeches or their external cocoons on the shell surfaces of crustaceans.



Crab leech

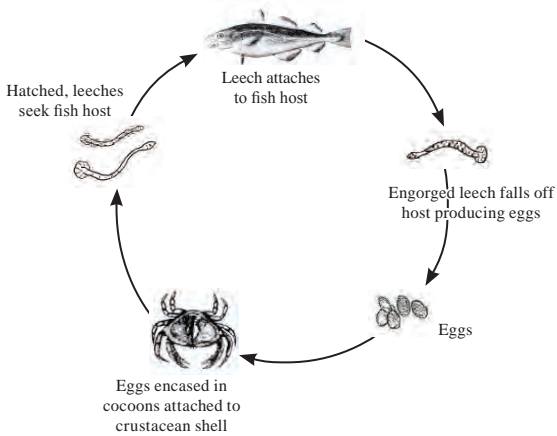


Crab leech attached to the carapace of a red king crab



Leech cocoons (arrow) deposited on the undersurface of the carapace of a golden crab

Crab Leech Life Cycle



Encysted Trematode Metacercariae

I. Causative Agent and Disease

Trematodes or flukes are members of the phylum Platyhelminthes and the class Trematoda. Adult worms of the subclass Digenea are endoparasites occurring in all classes of vertebrates and use invertebrates as the first and sometimes second intermediate host. A metacercaria is the encysted juvenile trematode usually occurring in the second intermediate host that requires ingestion by the final host to become an adult worm. Depending on the trematode species, metacercariae are found in a variety of tissues and intermediate hosts including crustaceans. Encysted metacercariae in most hosts generally cause no overt disease unless present in numbers large enough to damage major organs and tissues. Many of these worms have been identified belonging to the family Microphallidae including the genera *Microphallus*, *Spelotrema* and *Opecoeloides*.

II. Host Species

Encysted digenetic trematode metacercarial stages have been reported in several marine crustaceans including: penaeid shrimps from the southeastern U.S.; various Gulf coast crabs including the blue crab and blue crabs from Rhode Island; crangonid shrimp and Dungeness crabs from Washington State. In Alaska, unidentified metacercariae have been observed in Dungeness crabs and undoubtedly occur in other indigenous crab species as well.

III. Clinical Signs

There generally are no clinical signs of parasitism because the encysted metacercariae cause no significant tissue damage and are too small to observe grossly. An exception is the microphallid

parasitizing the Atlantic and Gulf coast blue crab that often itself is parasitized by the haplosporidian, *Urosporidium crescens*. The hyperparasite causes the fluke to become enlarged and darkly pigmented resulting in black spots visible within the flesh of the crab, a condition known as "buckshot" or "pepper" crab that renders the meats unmarketable.

IV. Transmission

Microphallid life cycles generally include a snail host producing swimming cercariae shed into seawater that horizontally parasitize a crustacean host producing metacercariae that must be eaten by a final host, usually a bird, mammal or rarely a cold-blooded vertebrate. The adult trematode matures in the intestine of the final host and produces eggs released into seawater with feces to begin the cycle again (see metacercariae in bivalve section).

V. Diagnosis

Wet mounts of fresh tissues may show the encysted metacercariae which are small and extremely difficult to find. Usually, encysted metacercariae are observed during routine histological examination in connective tissues, musculature, nervous tissues, hepatopancreas and gonads.

VI. Prognosis for Host

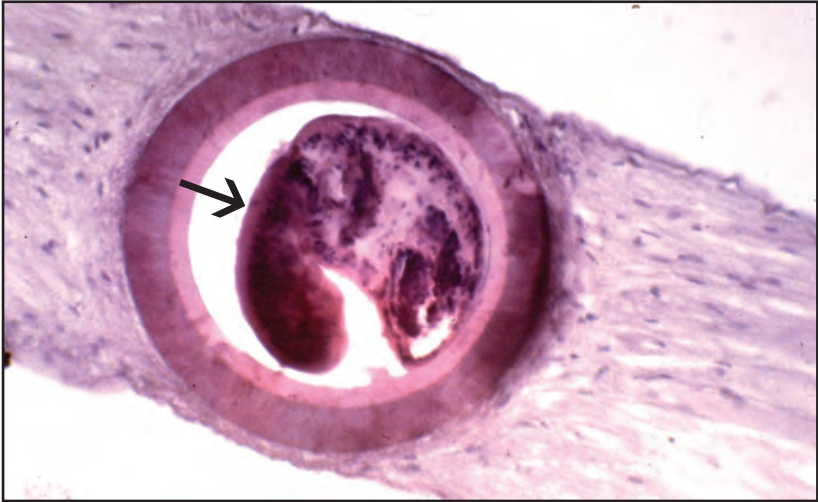Encysted trematode metacercariae generally cause no harm to the host except in isolated cases where large numbers may cause tissue necrosis and dysfunction. Ataxia resulting from necrosis or compression atrophy of nervous tissues could result when metacercariae occur in the nerves, brain or thoracic ganglion as reported for Dungeness

crabs and crangonid shrimp.

VII. Human Health Significance

Because microphallid trematodes use warm-blooded animals as the final

host there could be a zoonotic human health concern if encysted metacercariae in parasitized crab meats are consumed uncooked.



Encysted trematode metacercaria (arrow) in cranial nerve of Dungeness crab

Trypanorhynch Cestode Plerocercoids

I. Causative Agent and Disease

Trypanorhynch cestodes belong to the phylum Platyhelminthes, class Cestoda, order Trypanorhyncha and those having decapod crustaceans as intermediate hosts are found as adults in the alimentary tracts of elasmobranch final hosts. Reports of trypanorhynchid plerocercoids in crustaceans have largely been restricted to shrimp where high prevalences and intensities have been observed. In some shrimp species the worms are destroyed by host reaction causing granulomas in the hepatopancreas but no significant related mortality has been recognized. In a report of trypanorhynch plerocercoids (*Trimacracanthus aetobatidis* and *Dollfusiella martini*) in green crabs the worms cause epithelial metaplasia and loss of surrounding secretory parenchyma in digestive gland tubules and are also destroyed by a host mediated inflammation and encapsulation. In heavy infestations crab survival may be reduced.

II. Host Species

Penaeid shrimp species within Gulf coast waters of North America are the most common crustacean hosts reported to harbor trypanorhynch plerocercoids but the distribution of this order is worldwide and likely occurs in many other crustacean species such as reported from green crabs in Australia. In Alaska, a single unencysted specimen of a trypanorhynchid plerocercoid was recovered from the hepatopancreas of a captive red king crab collected from southeast waters.

III. Clinical Signs

There have been no significant clinical signs of plerocercoid infestation re-

ported in decapod crustaceans except for encapsulation and granuloma formation in the hepatopancreas and possibly other tissues. Conceivably, some host mortality or debilitation could result from heavy infestations.

IV. Transmission

Trypanorhynchid life cycles involving decapod crustaceans can include two general pathways starting with eggs released with feces from the elasmobranch final host followed by: eggs or hatched free-swimming ciliated coracidia are eaten by or infest a bivalve mollusc that is eaten by a decapod crustacean that is eaten by an elasmobranch; alternatively eggs or coracidia are eaten by or infest small crustaceans (copepod, amphipod) that are eaten by a larger decapod crustacean that is eaten by an elasmobranch. Coracidia develop into proceroids in the first intermediate host that later develop into plerocercoids in the last intermediate host.

V. Diagnosis

Diagnosis may be made by gross or histological observation of plerocercoids within the tissues of infested crustaceans. The scolex or head of a trypanorhynch plerocercoid has 2-4 bothria and 4 spiny eversible proboscides (tentacles).


VI. Prognosis for Host

There are no reports of significant decapod crustacean mortality or pathology associated with larval trypanorhynch infestations. An exception may be the trypanorhynchid plerocercoids infesting Australian green crabs where the parasites may possibly contribute to reduced crab survival.

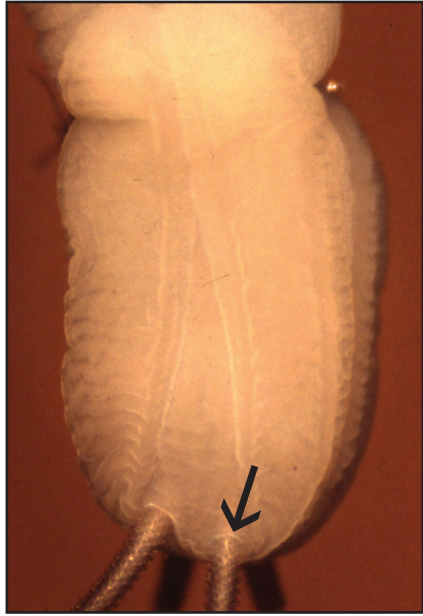
VII. Human Health Significance

There are no zoonotic human health concerns with the presence of trypano-

rhynch cestode larvae in the tissues of decapod crustaceans.

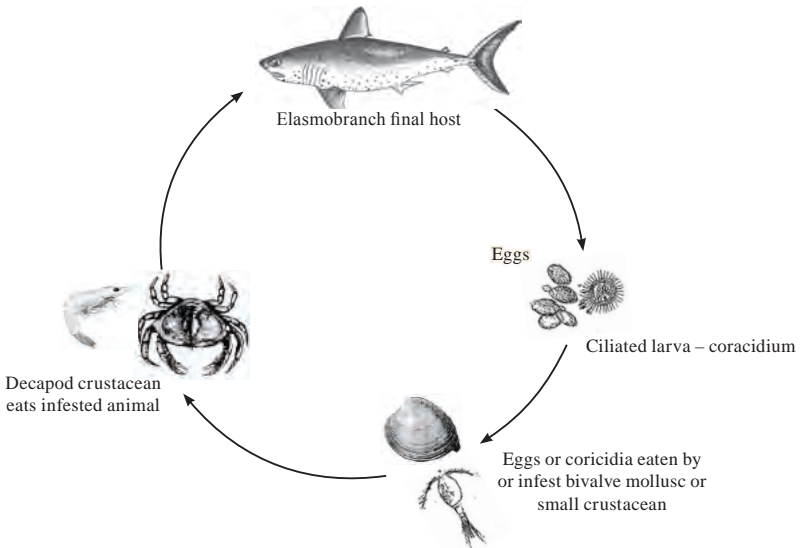


Trypanorhynch plerocercoid from red king crab showing posterior end



Trypanorhynch plerocercoid from red king crab showing scolex with bothria and 4 spiny proboscides (arrow)

Trypanorhynch Cestode Life Cycle



Briarosaccus callosis - Parasitic Barnacle

I. Causative Agent and Disease

Briarosaccus callosus is a parasitic barnacle belonging to the phylum Arthropoda, subphylum Crustacea, class Maxillopoda, subclass Thecostraca, infraclass Cirripedia (barnacles) and the superorder Rhizocephala (parasitic barnacles). Rhizocephalan barnacles are primarily parasites of decapod crustaceans but also occur in free-living barnacles and bivalve molluscs. They are noted for their invasiveness but general non-lethality in the natural host and endocrinological suppression of host fecundity at the population level.

II. Host Species

Briarosaccus callosus is a cosmopolitan rhizocephalan parasitizing several species of lithodid crabs most notably from the southeast coast of North America, Antarctica and sub Antarctic areas, southwest Indian Ocean, the Bering Sea, the Gulf of Alaska, southeast Alaska and British Columbia, Canada. Known crab species parasitized by *B. callosus* in Alaska include the red, blue and golden king crabs.

III. Clinical Signs

External clinical signs include a large orange/red sausage-shaped sac known as an externa that is attached by a stalk underneath the abdominal flap. The externa contains ova and/or larvae of the parasite. Radiating into the crab viscera from the externa is an emerald green dendritic mass or root system called the interna which largely replaces the hepatopancreas extending rootlets into all major organs and tissues of the visceral cavity including nerves and the bases of gills and muscle within the coxal joints. Gonads of both crab sexes are atrophied or absent. Parasitized male

crabs have an enlarged, raised abdominal flap and exaggerated growth of coxal setae. Histological examination confirms the extensive infiltration of tissues by the basophilic branching tubules of the rootlets generally causing no host inflammatory response. However, encapsulation of rootlets has been observed when the inflammatory response of the crab host is stimulated by a concurrent rickettsial infection.

IV. Transmission

The complete life history of *B. callosus* is not known but a portion of larval biology has been established to allow analogy with other known rhizocephalans. The externa is a double cylinder with an internal chamber containing ova that move into the outer chamber as the embryos mature causing the externa color to become pale orange. Stage I nauplii released from the externa become planktonic during which successive molts occur to the final stage IV before molting into a cyprid. As with other rhizocephalans, these cyprids are presumed to be the infectious stage and are sexually dimorphic in that one externa may produce cyprids that are small and female while another produces larger male cyprids. The smaller female cyprids attach to the gill lamellae of a crab host and molt to the kentrogon stage which injects a cell mass through a hollow stylet. These cells proliferate in the crab host becoming the female interna and reproductive externa. Newly emerged virginal externa do not reach sexual maturity until fertilized by larger male cyprids to begin the cycle again.

V. Diagnosis

Diagnosis is made by observation of the typical orange/red externa attached

by a stalk underneath the abdominal flap in lithodid crabs and the emerald green interna within the visceral mass. Parasitized crabs, including males, have feminized traits of an enlarged abdominal flap and a thick ventral growth of coxal setae, atrophied gonads and a protective behavior towards the attached externa. The externa utilizes hemoglobin as a respiratory pigment and bleeds red when damaged. Histological examination demonstrates the dendritic branches of the interna that retain the green pigment granules in fixed material.

VI. Prognosis for Host

Crabs are able to molt successfully with attached externa but the likelihood for long-term survival is not known once the parasite externa is lost or becomes senescent. Externa do not regenerate and the interna rootlets become atrophied



Dual parasitism of red king crab by *Briarosaccus callosus* showing viable externa (orange) and second senescent externa that has become necrotic (arrow)

and necrotic causing an intense inflammatory foreign body response that may kill the crab host. The parasite alters the endocrinology of the host crab causing atrophy of the gonads (castration) in both sexes and suppressed growth which effectively limit recruitment. The negative impact of this parasite on a population scale may be significant in certain areas depending on prevalences which have varied in southeast Alaska from less than 1% in red king crabs, 20% in golden king crabs and up to 76% in blue king crabs.

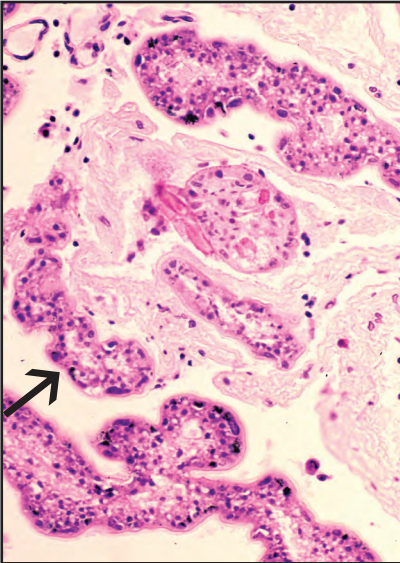
VII. Human Health Significance

There are no zoonotic human health concerns regarding parasitism of king crabs by *Briarosaccus callosus*. However, the rootlets may cause green discoloration of knuckle meats despite cooking.

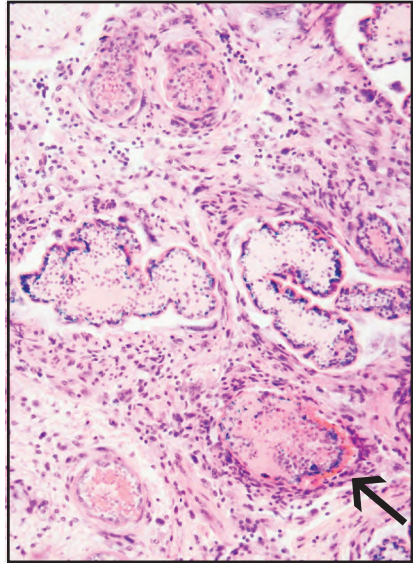


Cyprid larva of *Briarosaccus callosus* from the externa of parasitized blue king crab

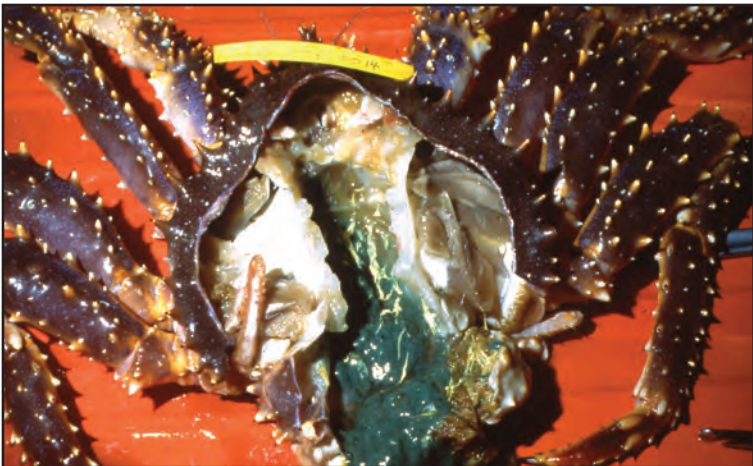
Briarosaccus callosus - Parasitic Barnacle



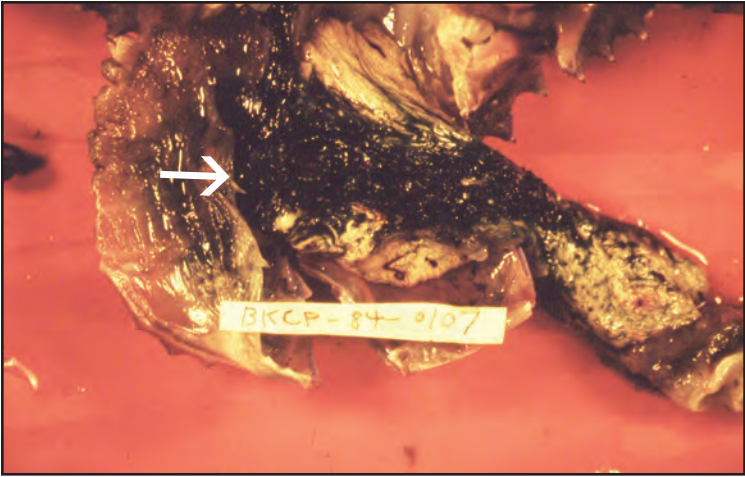
Histological section of blue king crab thoracic ganglion invaded by *Briarosaccus callosus* rootlets (arrow) of the interna with no host inflammatory response




Histological section of *Briarosaccus callosus* in another blue king crab infected with a rickettsia-like organism showing encapsulation of rootlets (arrow) by host cells



Briarosaccus callosus in blue king crab with typical green rootlet mass from healthy parasite externa



Parasitized blue king crab with missing externa resulting in black, atrophied and necrotic internal rootlet mass (arrow)



Blue king crab parasitized by *Briarosaccus callosus* showing atrophied yellow ovary (arrow) and obvious green rootlets of the interna in the hepatopancreas; compare with normal ovary on next page; note coagulated hemolymph nodule (arrowhead) resulting from concurrent infestation by the ciliate, *Mesanophrys* sp.

Digestive Tubular Degeneration and Bio-Fouling

I. Causative Agent and Disease

Digestive tubular degeneration appears to be a non-infectious lesion of the hepatopancreas observed in only two captive golden king crabs collected from southeast Alaska. Whether the condition occurs in wild crabs or is related to the stress of captivity is not known but affected crabs appear clinically normal. Bio-fouling is the external growth of algae, bacteria, bryozoa, barnacles and other epibionts on the cuticle and shell surface of crustaceans. Generally, the presence of these epibionts causes no harm to the crustacean host. However, heavy growth on the surface of gills or eyestalks could reduce respiratory capacity and sensory perception, respectively.

II. Host Species

Although noninfectious digestive tubular degeneration has been observed in only two captive Alaskan golden king crabs, the condition may occur in other captive crab species if related to stress. Bio-fouling may occur on any marine or freshwater crustacean species worldwide, the severity of which depends on the specific environmental conditions.

III. Clinical Signs

Digestive tubular degeneration causes no outward clinical signs but is visible on necropsy as black, brittle sections of hepatopancreatic tubules. Histological sections indicate areas of yellow-brown atrophied and necrotic digestive tubule acini surrounded by normal tubules. No causative agent is apparent using conventional stains. Bio-fouling may or may not be apparent by gross observation depending on the degree and the nature of the epibiont growth. Routine histological sections confirm the presence of epibiont

growth.

IV. Transmission

No infectious agent has been found for digestive tubular degeneration which may be related to the stress of captivity. Bio-fouling epibionts occur and reproduce in the water column and are passively transmitted horizontally.

V. Diagnosis

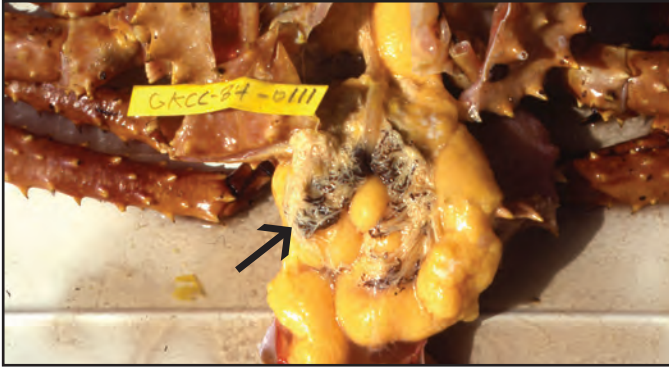
Digestive tubular degeneration is diagnosed by gross observation during necropsy and confirmed by histological examination. Bio-fouling may also be obvious but is confirmed by routine histological methods.

VI. Prognosis for Host

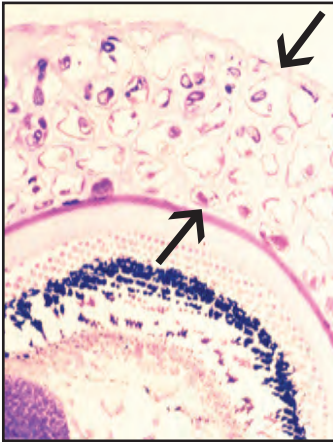
The clinical outcome of digestive tubule degeneration is unknown but affected crabs appear normal. Bio-fouling is generally harmless to adult crustaceans which shed the epibionts with the old shell during molting. Severe fouling of gills may result in shellfish mortality in areas having high organic pollution. Heavy epibiont growth by filamentous bacteria is known to cause mass mortality of captive larval red and blue king crabs when maintained at high densities.

VII. Human Health Significance

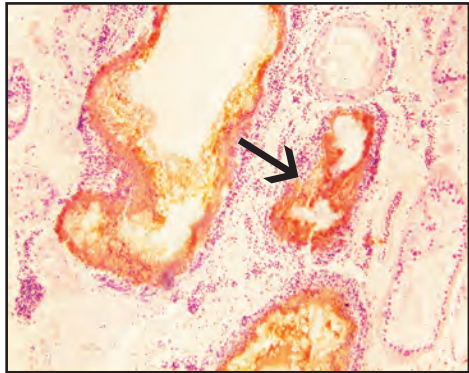
There are no zoonotic human health concerns regarding digestive tubular degeneration or bio-fouling in crustaceans.



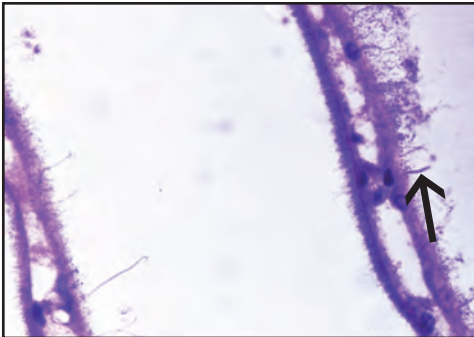
Female golden king crab with black sections of degenerated hepatopancreatic tubules (arrow); note normal yellow ovary underneath



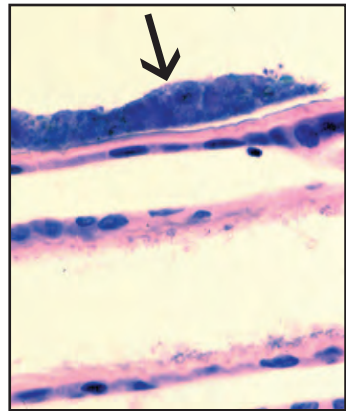
Histological section of eyestalk from Dungeness crab covered with bryozoan bio-fouling (arrows)



Atrophy and necrosis of tubule acini (arrow) in histological section of golden king crab with hepatopancreatic tubular degeneration



Histological section of gills from red rock crab demonstrating varied microbial bio-fouling (arrow)



Histological section of gills from blue king crab demonstrating bacterial bio-fouling (arrow)

Idiopathic Granulomatosis –Dungeness Crab

I. Causative Agent and Disease

Idiopathic (cause unknown) granulomatosis is a condition in Dungeness crabs where multiple granulomas are present histologically within the connective tissues of the midgut wall and rarely other tissues including the heart and bladder. Extensive histological examination using special stains have shown no evidence of an etiologic agent. It is possible that the cause may be environmental rather than a foreign body response to a biological entity. The granulomas appear to have no affect on crab health.

II. Host Species

Granulomatosis has been described in 34% of Dungeness crabs from Puget Sound, Washington and affecting 100% of Dungeness crabs inhabiting bark sediments at some logging transfer sites in southeast Alaska. Similar idiopathic granulomas have been described in penaeid shrimp and probably occur in other crustacean species in various oceans of the world.

III. Clinical Signs

There are no obvious clinical signs of idiopathic granulomatosis in Dungeness crabs which can only be detected by routine histological examination.

IV. Transmission

There is no current evidence to indicate that Dungeness crab granulomatosis is caused by a transmissible infectious agent. The high prevalence of granulomatosis accompanied by shell disease, loss of limbs, lower fecundity and mortality in Dungeness crabs associated with benthic deposits of decomposing bark and sulfide at logging transfer sites (see shell disease section) in southeast Alaska

suggest a potential toxic etiology. Other environmental causes may be associated with granulomatosis described in Dungeness crabs from different locations.

V. Diagnosis

Diagnosis is by routine histological examination of Dungeness crab tissues showing multiple granulomas in the connective tissues of the midgut wall. These lesions are typically of two types. Type one is smaller, more frequent, consists of a melanized center with few surrounding hemocytes and is located throughout the midgut wall. The second type is larger, less common and is located deeper within the connective tissues of the midgut wall and has a central melanized core surrounded by a large collar of hemocytes. The differences in the size, morphology and location of the two types of granulomas have caused speculation that they are reactions to two different stimuli. These granulomas can be found in other tissues including the heart and bladder.

VI. Prognosis for Host

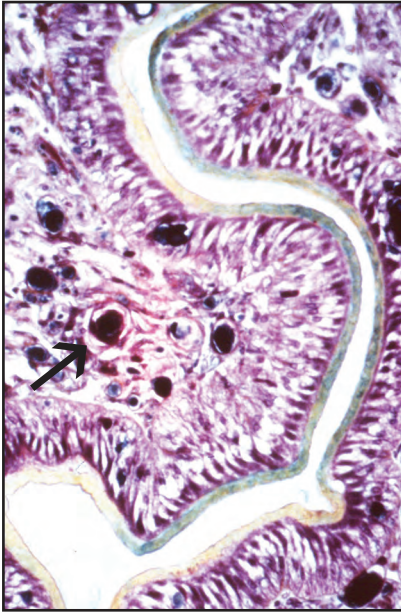
There has been no obvious host morbidity or debilitation associated with idiopathic granulomatosis in Dungeness crabs.

VII. Human Health Significance

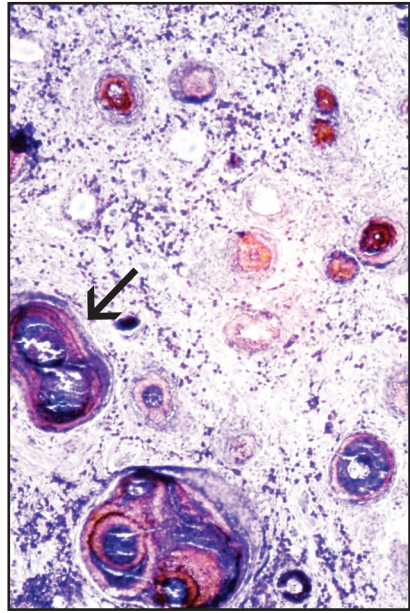
There is no zoonotic human health concern associated with this condition in Dungeness crabs.



Typical Dungeness crab



Histological section of smaller type 1 granulomas (arrow) in the midgut connective tissues of Dungeness crab



Histological section of larger type 2 granulomas (arrow) in the midgut connective tissues of Dungeness crab

Proliferative Lesions and Neoplasia

I. Causative Agent and Disease

Reports of abnormal proliferation of tissues in marine decapod crustaceans have been extremely rare. There have been less than a dozen cases in the literature of which only four have shown convincing evidence of cancer. Cancers or neoplasms are growths of abnormal cells that proliferate uncontrollably and have no useful function as opposed to cells that are normal that may proliferate excessively (hyperplasia) due to some functional demand or stimulus.

II. Host Species

Reports of neoplasia have included lymphosarcoma of hematopoietic tissues in two cultured penaeid white shrimp from Hawaii, a carcinoma of the hindgut and an adenocarcinoma of the antennal gland in Alaskan red and blue king crabs, respectively, and embryonal carcinoma in developing embryos of cultured grass shrimp in Taiwan. Additional studies in Alaska have discovered two other cases of probable tegmental gland adenocarcinoma in a blue and golden king crab.

III. Clinical Signs

Clinical signs of proliferative diseases can include obvious external tissue growths but more frequently the abnormal tissues are found during routine necropsy and histological examination.

IV. Transmission

Certain proliferative lesions may be simple hyperplasia and inflammation in response to an infectious agent or foreign body. Most neoplasms or cancers are considered spontaneous resulting from environmental contamination, congenital malformation, age or genetic predis-

position and are not transmissible in nature. Exceptions are cancers caused by infectious viruses of which none have been documented as causing neoplasia in decapod crustaceans. There have been three cases of probable tegmental gland adenocarcinoma in two blue and one golden king crab in which an aquabirna-like virus (discussed elsewhere) was observed in one affected crab but the true etiology of that neoplasm is not known.

V. Diagnosis

Neoplasms are diagnosed and classified using histological methods to determine the cell or tissue of origin and are further grouped based on benign or malignant characteristics. Benign tumors are often well-differentiated, grow slowly, are well circumscribed without invading surrounding normal tissue and do not metastasize. Most benign neoplasms usually end in the suffix "oma". Exceptions are benign neoplasms of the brain and some endocrine organs in higher vertebrates that can be life threatening due to their location and deleterious physiological effects on the host. Malignant tumors are often not well differentiated, may grow rapidly, infiltrate normal tissues and tend to metastasize. The names of these neoplasms are often preceded by the word "malignant" or with the suffixes "sarcoma" or "carcinoma". Three of the four neoplasms observed in Alaskan king crabs are considered to be tegmental gland adenocarcinomas affecting the antennal gland, midgut, hepatopancreas and muscle tissues and appear to metastasize. These neoplasms range in histological appearance from: mostly inflammatory with hemocyte infiltration, fibroplasia and cell necrosis to a highly cellular

mass of streaming and nested fibroblastic cells surrounding glandular basophilic acinar-like structures or a highly cellular solid mass of large basophilic cells with bizarre nuclei that also form occasional glandular acinar-like structures. The underlying neoplastic cell present in varying frequencies in all presentations is an anaplastic large basophilic cell with a large clefted bizarre shaped nucleus having one to three eosinophilic nucleoli. These cells sometimes form multinucleated giant cells and occasionally are observed inside phagocytic host cells. Mitotic figures in acinar-like structures are present.

VI. Prognosis for Host

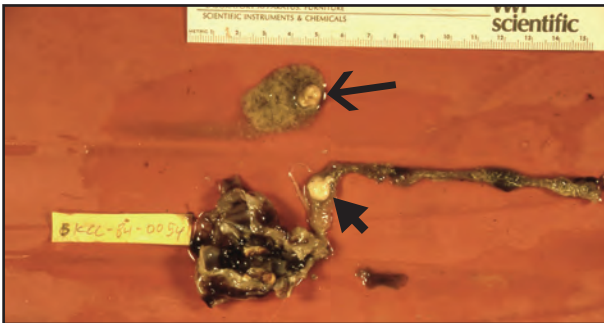
Proliferative lesions of an inflammatory or hyperplastic nature are generally reversible and not life threatening

depending upon the tissue location and if the irritating cause can be removed. True neoplasia usually results in death of the affected animal.

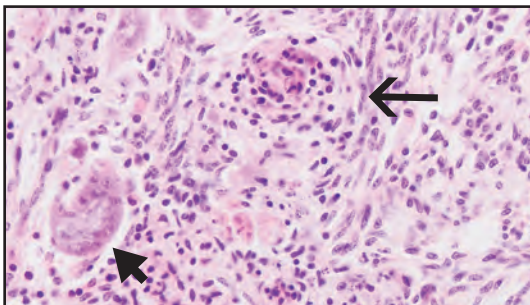
VII. Human Health Significance

Although aesthetically disturbing, there are no zoonotic human health concerns associated with proliferative lesions or neoplasia in decapod crustaceans. Proliferative inflammatory lesions may suggest an infectious agent that could negatively affect the desirability of the meats for human consumption. Cancer is an extremely rare event in decapod crustaceans and, therefore, should neoplasia be found to occur more frequently in a population, an indirect human health concern would be whether the cause is linked to environmental contamination.

Note: all figures are of suspected tegmental gland adenocarcinomas in blue and golden king crabs

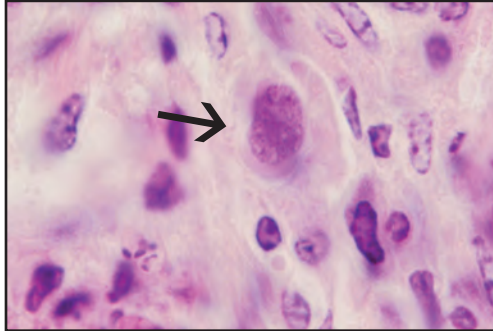


White neoplastic nodular masses on hepatopancreas (arrow) and midgut (arrowhead) of a blue king crab

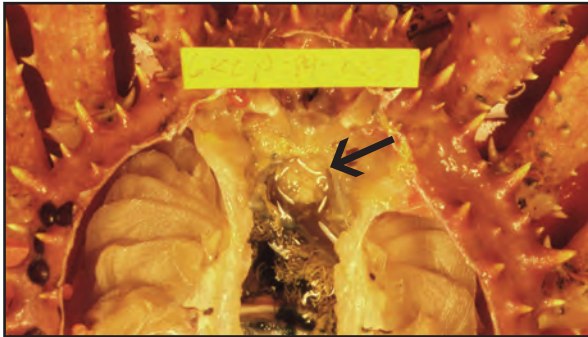


Histological section of midgut neoplasm above showing streaming fibroblasts (arrow) and acinar-like structures (arrowhead)

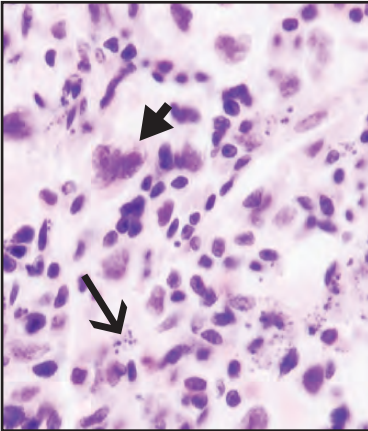
Proliferative Lesions and Neoplasia



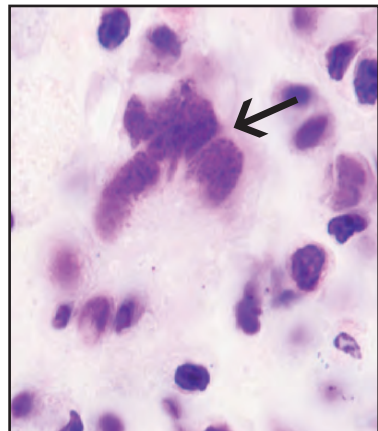
A second histological section of nodule on previous page showing occasional large anaplastic cell (arrow) with large nucleus



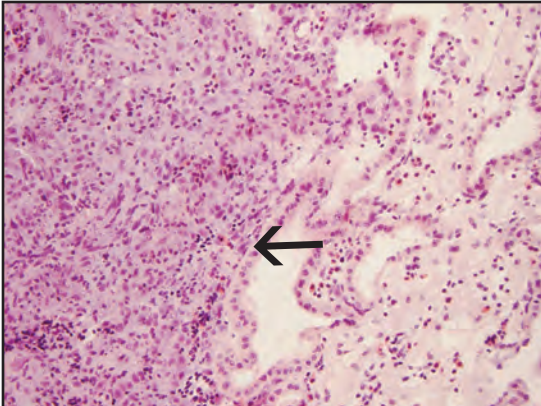
Golden king crab with a white nodular neoplasm in dorsal connective tissue and musculature (arrow)



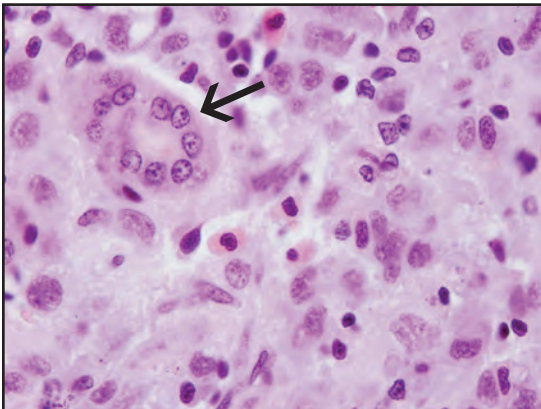
Histological section of Inflammatory cells, necrotic debris (arrow) and large cells with bizarre-shaped nuclei (arrowhead) from golden king crab nodular mass



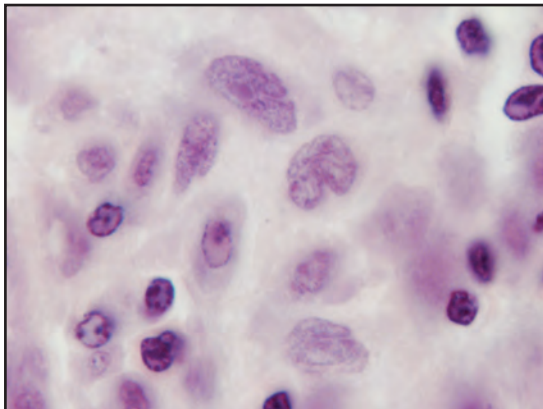
Same neoplasm showing multinucleated giant cell (arrow)



Histological section of a second blue king crab with basophilic cellular neoplasm (arrow) in antennal gland (published report)



Large cells with bizarre-shaped clefted nuclei and occasional acinar-like structures (arrow) from blue king crab neoplasm above



Higher magnification of same neoplastic cells with bizarre nuclei

Glossary of Terms

Acid-fast - a physical property of the cell walls in some bacteria and protozoa that resists de-colorization by acids during the staining procedure.

Amphipod - a small crustacean of the order Amphipoda, having a laterally compressed body with no carapace.

Anaplastic - relating to cells that have become less differentiated and more embryonic.

Antennal gland - one of the pair of excretory organs (functional kidney) in each side of the head region of decapod crustaceans, emptying at the base of the antennae.

Arthropod - belonging to the phylum Arthropoda, an insect or crustacean that has a cuticle made of chitin forming an exoskeleton with segments and jointed appendages.

Ataxia - loss of the ability to coordinate muscular movement.

Bacteria - any of a large group of unicellular prokaryotic organisms that lack a cell nucleus, reproduce by fission or by forming spores, and in some cases cause disease.

Basophilic - tissue components having an affinity for dye under basic pH conditions (as in histology) that generally stain blue.

Bioaccumulation - the accumulation of particles such as viruses or bacteria in various tissues of bivalve molluscs by the filter feeding mechanism.

Bivalve - any mollusc, such as oysters,

clams, scallops, or mussels, of the class Bivalvia having two shells hinged together, a soft body, and lamellate gills.

Bothria- shallow sucking grooves on the scolex of a tapeworm.

Carapace - The shell or exoskeleton covering the head, thorax, and legs of a crustacean.

Carrier - an individual animal with an asymptomatic infection which is capable of being transmitted to other susceptible individuals.

Catalase - enzyme found in most plant and animal cells that functions as an oxidative catalyst; decomposes hydrogen peroxide into oxygen and water.

Cephalopod - any mollusc of the class Cephalopoda, having tentacles attached to the head, including the cuttlefish, squid, and octopus.

Cercaria - free swimming larva of flukes of the class Trematoda, having a tail-like appendage; stage usually released from the mollusc first intermediate host.

Cestode - a tapeworm possessing a modified end segment called a scolex that is used for attachment. Tapeworms generally require three hosts for development.

Chlamydia - genus including coccoid to spherical Gram-negative intracellular parasitic bacteria that have three developmental forms.

Chromatin - the readily stainable substance of a cell nucleus consisting of DNA and RNA and various proteins;

during mitotic division it condenses into chromosomes.

Commensalism - a symbiotic relationship between two organisms of different species in which one derives some benefit while the other is unaffected.

Conchiolin - a fibrous protein substance that is the organic basis of mollusc shells.

Conidia - an asexually produced fungal spore, formed on a conidiophore.

Copepod - small planktonic crustaceans which are an important part of the aquatic food chain.

Copepodid - juvenile stages that follow the naupliar stages in copepods, often similar in body form to the adult.

Coracidium - a ciliated larval stage of a tapeworm hatching from the egg which infests the first intermediate mollusc or crustacean host.

CPE (Cytopathic Effect) - damage to cultured cells caused by virus infection.

Crustacean - an arthropod having a segmented body and jointed appendages, with two pairs of antennae at some stage in their life cycle.

Cuticle - the outer, non-cellular layer of the arthropod integument, composed of a mixture of chitin and protein.

Cyst - a capsule of connective tissue formed by the host around a foreign body, such as a parasite, that acts as an irritant.

Cytoplasm - the fluid-like substance that fills the cell, consisting of cytosol and organelles excluding the nucleus.

Decapod - crustaceans characteristically having five pairs of locomotor appendages each joined to a segment of the thorax.

Denticles - small tooth or tooth-like projections.

Dinoflagellate - any of numerous minute, chiefly marine protozoans of the order Dinoflagellata that have a trilaminar alveolate pellicle covering and produce spores having two flagella.

Diplobacilli - paired rod shaped bacterial cells.

DNA - deoxyribonucleic acid that contains genetic information for the reproduction, development and function of living organisms including some viruses.

Ecdysis - shedding of the old shell or the process of molting.

Ectoparasite - a parasite that lives on the surface or exterior of the host organism.

Elasmobranch - any of numerous fishes of the class Chondrichthyes, characterized by a cartilaginous skeleton and placoid scales that includes the sharks, rays, and skates.

Electron microscopy - use of an electron microscope that generates an electron beam focused through a series of objectives and lenses to create an image for observing ultrastructural details at a much higher magnification than a traditional light microscope.

Encyst - to enclose in a cyst.

Endoparasite - a parasite that lives within the body of another organism rather than on the surface.

Eosinophilic - a red color of cells or

tissues in histological sections or stained smears that have been stained with eosin or other acid dyes.

Epibiont - an organism that uses the body surface of another as a substrate but takes no nourishment or other benefit.

Epithelium - one or more layers of specialized cells forming the covering of most internal and external surfaces of the body and its organs and comprising glandular elements of certain organs.

Epizootic - an outbreak of a disease in an animal population or an unusually large increase in prevalence and/or intensity of a parasite.

Exoskeleton - a hard outer structure, such as the shell of an insect or crustacean, that provides protection or support for an organism.

Exotoxin - a poisonous substance secreted by a microorganism and released into the medium in which it grows.

Extracellular - outside the cell.

Facultative parasite - an organism that may either lead an independent existence or live as a parasite.

Final host - (definitive host) the host in which a parasite develops to an adult form and reproduces.

Fluorescent antibody test (FAT) - a test using antibody against a specific pathogen that is conjugated with a fluorescein dye. The conjugated antibody sticks to the target organism causing fluorescence when viewed with a fluorescent microscope.

Fungi - heterotrophic organisms that may exist in a symbiotic, saprophytic or para-

sitic relationship to obtain their nutrients.

Gametocytes - a cell from which gametes (spermatocyte or oocyte) develop by meiotic division.

Gamogony - sexual reproduction in protozoa (anisogamy).

Gastropod - any of various molluscs of the class Gastropoda characteristically having a single, usually coiled shell or no shell at all, a ventral muscular foot for locomotion, and eyes and tentacles located on a distinct head.

Genome - the total genetic content contained in a haploid set of chromosomes in eukaryotes, in a single chromosome in bacteria, or in the DNA or RNA of viruses.

Germ ball - a group of undifferentiated cells in digenetic trematode miracidial larvae and sporocysts that form either sporocysts or rediae and finally cercariae.

Gram-negative rod - a rod shaped bacterium that does not retain the crystal violet in the Gram stain process, but retains the counter stain and is pink in color.

Gram-positive rod - a rod-shaped bacterium that retains the crystal violet from the Gram stain process and is dark purple in color.

Granuloma - a chronic focal inflammatory lesion that walls off a foreign body or necrotic tissues and may consist of several elements including different types of host inflammatory cells and fibroblastic connective tissue.

Gregarine - a sporozoan parasite utilizing molluscs as intermediate hosts and crustaceans as final hosts.

Hemocyte - general term for several types of cellular components of the blood in an invertebrate.

Hemolymph - the circulatory fluid of invertebrates, including all arthropods and most molluscs, that have an open circulatory system. Hemolymph is analogous to blood and lymph in vertebrate animals and consists of water, amino acids, inorganic salts, lipids, sugars and usually hemocyanin as a respiratory pigment.

Hepatopancreas - a large digestive gland of shrimps, lobsters, and crabs that combines the functions of a liver and pancreas.

Hermaphrodite - an individual having reproductive organs of both sexes.

Histological (histology) - the microscopic anatomy of cells and tissues as viewed in thin stained tissue sections on glass slides.

Hyperplasia - an increase in the growth of cell numbers of a tissue or organ that may or may not increase in overall size; usually stimulated by an irritant.

Hypertrophy - a non-cancerous enlargement of a cell, organ or tissue as a result of an increase in the size rather than the number of constituent cells.

Hyphae - long branching vegetative filaments of a fungus.

Inflammation - a host cellular response to tissue damage or irritation in invertebrates sometimes causing dysfunction of the tissues and organs involved.

Intermediate host - a host in which there is development of the asexual or immature stage of a parasite.

Latent - remaining in an inactive or hidden phase; dormant.

Lethargy - a state of sluggishness or inactivity.

Macronucleus - the larger of two nuclei present in ciliate protozoans which controls cell metabolism and growth.

Mantle - an outgrowth of the body wall that lines the inner surface of the valves of the shell in molluscs and brachiopods.

Melanin - a tyrosine derived polymeric brown to black pigment produced by melanocytes within the tissues of vertebrates and invertebrates.

Merogony - also called schizogony, the asexual reproduction of various protozoans involving multiple fission of a trophozoite or schizont into merozoites.

Meront - a stage in the life cycle of various protozoans in which multiple asexual fission (schizogony) occurs, resulting in the production of merozoites.

Metacercaria - an encysted cercaria of a digenetic trematode that develops into a juvenile trematode, usually within the second intermediate host.

Metaplasia - the transformation of one type of tissue or cell into another.

Metastasize - dissemination of neoplastic cells from a primary tumor to other parts of the body producing secondary tumors.

Micronucleus - the smaller of two nuclei in ciliate protozoans that contains genetic material that controls reproduction.

Miracidium - the ciliated larval stage of a digenetic trematode hatching from the egg which infests the first intermediate

mollusc host.

Mollicutes - an unusual class of very small bacteria that live a parasitic existence within host cells and are distinguished by the absence of a cell wall; commonly called mycoplasmas.

Mollusc - any invertebrate of the phylum Mollusca, typically having a calcareous shell of one, two, or more pieces that wholly or partly enclose the soft, unsegmented body, including the chitons, snails, bivalves, squids, and octopuses.

Mycoplasma - any of numerous parasitic microorganisms of the class Mollicutes comprising the smallest self-reproducing prokaryotes, lacking a true cell wall and able to survive without oxygen.

Mycosis - fungal infection.

Nauplius - the free-swimming first larval stage of various crustaceans having an unsegmented body with three pairs of appendages and a single median eye.

Necropsy - a postmortem examination of an animal.

Necrosis - the death of cells or tissues from traumatic injury or disease, generally in a localized area of the body.

Neoplasms/neoplasia - cancer caused by uncontrolled abnormal growth of tissue cells.

Nucleolus - one or more small, typically round granular body composed of protein and RNA in the nucleus of a cell, usually associated with a specific chromosomal site and involved in ribosomal RNA synthesis and the formation of ribosomes.

Nucleoplasm - the jelly-like material within a cell nucleus containing the

nucleolus and chromatin.

Obligate parasite - an organism that cannot lead an independent nonparasitic existence.

Oocyst - the encysted zygotic stage in the life cycle of some sporozoans.

Palps - in bivalve molluscs - folds of gill-like tissues surrounding the mouth which receive food collected by the gills.

Parasite - an organism that lives on or in another organism at whose expense it obtains some advantage.

PAS - periodic acid-Schiff stain which is primarily used to identify glycogen in histological sections that is useful in detecting fungi and some protozoa.

Pathogen - an infectious agent that can cause disease.

PCR - polymerase chain reaction is a test that amplifies targeted DNA or RNA that has been converted to DNA through a reverse transcription process.

Phagocytosis - process in which host hemocytes engulf and digest microorganisms and cellular debris; an important defense against infection for invertebrates.

Plaque Forming Unit (PFU) - number of infectious virus particles per unit volume based on the number of holes or plaques in the monolayer of the infected cell culture.

Plasmodia - multinucleated reproductive cells in various protozoa that develop into sporonts and sporocysts containing or producing spores.

Plerocercoid - the third larval stage of cestodes that has an obvious scolex.

Generally found in the second intermediate host.

Poikilothermic - animals or agents that occur in animals with internal body temperatures that cannot be self regulated, often determined by the ambient temperature of the environment; cold blooded.

Polar tube - a hollow tube in microsporidians that anchors the spore to the intestinal wall of the prospective host through which the organism is injected.

Polychaete - any of various often brightly colored annelid worms of the class Polychaeta. Each segment of a polychaete has a pair of fleshy appendages that are tipped with bristles (setae), used for swimming or burrowing.

Proboscis - any of various elongate feeding, defensive, attachment or sensory organs of the oral region, found in certain leeches and worms.

Proceroid - the first stage in the aquatic life cycle of certain tapeworms following ingestion of the newly hatched coricidium larva by a mollusc or copepod.

Prognosis - a prediction of how a disease will progress, and the chance for recovery.

Prokaryote - an organism of the kingdom Monera (or Prokaryotae), comprising the bacteria and cyanobacteria, characterized by the absence of a distinct, membrane-bound nucleus or membrane-bound organelles, and by DNA that is not organized into chromosomes.

Protozoa - any of a large group of single-celled, usually microscopic, eukaryotic organisms, such as amoebas, ciliates, flagellates, sporozoans, microspora and

haplosporidians.

Pycnidia - an asexual structure containing conidia, found in certain fungi.

Rickettsia - any member of the family Rickettsiaceae, comprising rod-shaped to coccoid microorganisms that resemble bacteria and reproduce only inside a living cell.

RNA - ribonucleic acid; the nucleic acid that is used in key metabolic processes for all steps of protein synthesis in all living cells and carries the genetic information for many viruses.

Saprophyte - an organism, such as a fungus, bacterium or protozoan that grows on and derives its nourishment from dead or decaying organic matter.

Scolex - the head segment of a cestode that attaches to its host.

SEM - scanning electron microscopy.

Septate - describing fungal hyphae that are divided by crosswalls or septa.

Septicemia - presence of bacteria or other organisms in the blood.

Serotype - a unique antigenic property of a bacterial cell, virus or other organism identified by serological methods.

Setae - stiff hairs, bristles, or bristle-like processes that are part of the body of an organism.

Spat - a juvenile oyster or similar bivalve mollusc that has settled out of the water column and has developed a shell.

Sporangia - a single or many celled structure from which spores or zoospores are produced in a fungus.

Spore - a reproductive structure that is adapted for dispersion and survival for extended periods of time in unfavorable environmental conditions.

Sporoblast - in some sporozoa, an early stage in the development of a sporocyst, prior to differentiation of the sporozoites. In microspora a sporoblast matures into a spore.

Sporocyst - in sporozoa, a walled body resulting from multiple division which produces one or more sporozoites; in microspora, haplosporidia and *Hematodinium* sp. a walled body that contains or produces spores; in trematoda, an elongated stage in the first intermediate host that produces more sporocysts or rediae depending on the species of fluke. The end product of both is cercariae.

Sporogony - asexual reproduction by multiple fission of a spore or zygote. Sporogony in sporozoans results in the production of sporozoites, or sporonts in microspora, haplosporidia and *Hematodinium* sp.

Sporont - in the sexual reproduction of certain sporozoans, an encysted spore developed from a zygote, which undergoes sporogony to form sporozoites. In certain microspora, sporogony produces sporonts that produce sporoblasts that mature into spores. In haplosporidia and *Hematodinium* sp. sporonts become sporocysts that produce spores.

Sporozoite - minute undeveloped infectious stages of sporozoans produced by multiple fission of a zygote or spore.

Syncytia - the fusing of separate cells to form a larger multinucleated cell.

TEM - transmission electron microscopy.

Trematode - a flatworm having a complex (digenetic) life cycle involving two or three hosts. Also referred to as a fluke.

Trophozoite - active, feeding stage of a protozoan.

Turbellarian - belonging to the Turbellaria, a class of platyhelminths or flatworms, mostly aquatic and having cilia on the body surface.

Vector - any agent (person, animal or microorganism) that carries and transmits a disease.

Virulence - the pathogenicity or ability of an infectious agent to produce disease.

Viscera - internal organs of an animal.

Virus - a very small infectious agent composed of a nucleic acid core (RNA or DNA) surrounded by a protein coat that replicates only within living host cells.

Zooflagellate - any flagellated protozoan that lacks photosynthetic pigment and feeds on organic matter; often parasitic.

Zoonotic - a disease of an animal that can be transmitted to humans.

Shellfish Disease References

- Bower, S.M., J. Blackbourn and G.R. Meyer. 1992. Parasite and symbiont fauna of Japanese littleneck clams, *Tapes philippinarum* (Adams and Reeve, 1850), in British Columbia. *Journal of Shellfish Research* 11: 13-19.
- Bower, S.M., S.E. McGladdery and I.M. Price. 1994. Synopsis of infectious diseases and parasites of commercially exploited shellfish. *Annual Review of Fish Diseases* 4:1-199.
- Caceres-Martinez, J. and R. Vasquez-Yeomans. 1997. Presence and histopathological effects of the copepod *Pseudomyicola spinosus* in *Mytilus galloprovincialis* and *Mytilus californianus*. *Journal of Invertebrate Pathology* 70: 150-155.
- Couch, J.A. and J.W. Fournie (eds.). 1993. *Pathobiology of Marine and Estuarine Organisms*. CRC Press, Boca Raton, Florida.
- Dare, P.J. 1981/1982. The susceptibility of seed oysters of *Ostrea edulis* L. and *Crassostrea gigas* Thunberg to natural infestations by the copepod *Mytilicola intestinalis* Steuer. *Aquaculture* 26: 201-211.
- Dixon, P.F., G.-H. Ngoh, D.M. Stone, S.F. Chang, K. Way and S.L.F. Kueh. 2008. Proposal for a fourth aquabirnavirus serogroup. *Archives of Virology* 153: 1937-1941.
- Ellis, A. 1985. *Fish and Shellfish Pathology*. Academic Press, Orlando, Florida.
- Elston, R.A. 1990. *Mollusc Diseases: Guide to the Shellfish Farmer*. Washington Sea Grant Program, University of Washington Press, Seattle and London.
- Elston, R.A., J.D. Moore and K. Brooks. 1992. Disseminated neoplasia of bivalve molluscs. *Reviews in Aquatic Sciences* 6: 405-466.
- Elston, R.A. 1999. *Health Management, Development and Histology of Seed Oysters*. World Aquaculture Society, Baton Rouge, Louisiana.
- Elston, R.A., H. Hasegawa, K.L. Humphrey, I.K. Polyak and C.C. Häse. 2008. Re-emergence of *Vibrio tubiashii* in bivalve shellfish aquaculture: severity, environmental drivers, geographical extent and management. *Diseases of Aquatic Organisms* 82: 119-134.
- Fisher, W.S. (ed.) 1988. *Disease Processes in Marine Bivalve Molluscs*. American Fisheries Society Special Publication 18, Bethesda, Maryland.
- Hawkes, C.R., T.R. Meyers and T.C. Shirley. 1985. Larval biology of *Briarosaccus callosus* Boschma, (Cirripedia: Rhizocephala). *Proceedings of the Biological Society of Washington*. 98: 935-944.

REFERENCE

- Kennedy, V.S., R.I.E. Newell and A.F. Eble (eds.). 1996. The Eastern Oyster *Crassostrea virginica*. Maryland Sea Grant College, College Park, Maryland.
- Kinne, O. (ed.) 1980-1984. Diseases of Marine Animals. John Wiley and Sons, New York and Biologische Anstalt Helgoland, Hamburg, Germany. Vol. 1-4.
- Kuris, A.M. and D.E. Wickham. 1987. Effect of nemertean egg predators on crustaceans. *Bulletin of Marine Science* 41: 151-164.
- Lauckner, G. 1983. Diseases of mollusca: bivalvia. pgs 477-961 In Kinne, O (ed.) Diseases of Marine Animals Vol. III, Biologische Anstalt Helgoland, Hamburg, Germany.
- Lom, J. and I. Dykova. 1992. Protozoan Parasites of Fishes. Elsevier Science Publishers, B.V., Amsterdam.
- Meyers, T.R. 1981. Endemic diseases of cultured shellfish of Long Island, New York: Adult and juvenile American oysters (*Crassostrea virginica*) and hard clams (*Mercenaria mercenaria*). *Aquaculture* 22: 305-330.
- Meyers, T.R. 1985. Marine bivalve molluscs as reservoirs of viral finfish pathogens: significance to marine and anadromous finfish aquaculture. *Marine Fisheries Review* 46(3): 14-17.
- Meyers, T.R. 1990. Diseases of crustacea - diseases due to protistans and metazoans, pgs 350-389 In Kinne, O (ed.) Diseases of Marine Animals Vol. III, Biologische Anstalt Helgoland, Hamburg, Germany.
- Meyers, T.R., S. Short and W. Eaton. 1990. Diseases of five commercial crab species in Southeast Alaska, pgs 407-420 In Cheng, C and F. Perkins, (eds.) Pathology in Marine Science, Academic Press, New York.
- Meyers, T.R., S. Short and W. Eaton. 1990. Summer mortalities and incidental parasitisms of cultured Pacific oysters in Alaska. *Journal of Aquatic Animal Health*. 2: 172-176.
- Meyers, T.R., D.V. Lightner and R.M. Redman. 1994. A dinoflagellate-like parasite in Alaskan spot, *Pandalus platyceros*, and pink, *P. borealis*, shrimp. *Diseases of Aquatic Organisms* 18:71-76.
- Meyers, T.R., J.F. Morado, A.K. Sparks, G.H. Bishop, T. Pearson, D. Urban and D. Jackson. 1996. The distribution of bitter crab syndrome in Tanner crabs (*Chionoecetes bairdi*, *C. opilio*) from the Gulf of Alaska and the Bering Sea. *Diseases of Aquatic Organisms* 26: 221-227.
- Morado, J.F., A.K. Sparks and S.K. Reed. 1984. A coccidian infection of the kidney of the native littleneck clam, *Protothaca staminea*. *Journal of Invertebrate Pathology* 43: 207-217.

REFERENCE

- Morado, J.F. and E.B. Small. 1995. Ciliate parasites and related diseases of Crustacea: a review. *Reviews in Fisheries Science* 3: 275-354.
- Overstreet R.M. 1978. Marine Maladies? Worms, Germs and Other Symbionts From the Northern Gulf of Mexico. Mississippi-Alabama Sea Grant Consortium, MASGP-78-021.
- Perkins, F. O. and T. Cheng. (eds.). 1990. *Pathology in Marine Science*. Academic Press. San Diego, California.
- Peters, E.C., P.P. Yevich, J.C. Harshbarger and G.E. Zaroogian. 1994. Comparative histopathology of gonadal neoplasms in marine bivalve molluscs. *Diseases of Aquatic Organisms* 20: 59-76.
- Proceedings of the Symposium on Dungeness Crab Biology and Management, April 1985, Anchorage, AK, University of Alaska, Alaska Sea Grant Report. No. 85-3.
- Proceedings of the International King Crab Symposium, November 1985, Anchorage, AK, University of Alaska Sea Grant Report No. 85-12.
- Proceedings of the International Symposium on King and Tanner Crabs, 1989, Anchorage, AK, University of Alaska Sea Grant College Program Report No. 90-04.
- Provenzano, Jr. A.J. (ed.). 1983. Pathobiology Vol. 6 in D.E. Bliss (ed.-in-chief) *The Biology of Crustacea*. Academic Press, New York, New York.
- Shields, J.D., D.E. Wickham and A.M. Kuris. 1989. *Carcinonemertes regicides* n.sp. (Nemertea), a symbiotic egg predator from the red king crab, *Paralithodes camtschatica* (Decapoda: Anomura), in Alaska. *Canadian Journal of Zoology* 67: 923-930.
- Sindermann, C.J. 1990. *Principal Diseases of Marine Fish and Shellfish Vol. 2 Diseases of Marine Shellfish*. Academic Press, Inc., San Diego, California.
- Sloan, N.A., S.M. Bower and S.M.C. Robinson. 1984. Cocoon deposition on three crab species and fish parasitism by the leech *Notostomum cyclostoma* from deep fjords in northern British Columbia. *Marine Ecology Progress Series* 20: 51-58.
- Sparks, A.K. 1985. *Synopsis of Invertebrate Pathology Exclusive of Insects*. Elsevier Science Publishers B.V., New York, New York.
- Stentiford, G.D. and J.D. Shields. 2005. A review of the parasitic dinoflagellates *Hematodinium* species and *Hematodinium*-like infections in marine crustaceans. *Diseases of Aquatic Organisms* 66: 47-70.

Notes

