

Steinhausia sp. and Other Unidentified Microsporidia

I. Causative Agent and Disease

Microsporidia is a protozoan order within the class Microsporea within the phylum Microspora. However, there is controversial genetic evidence for a closer affinity to the kingdom of Fungi rather than Protozoa. A small number of Microspora parasitize marine bivalves. They are intracellular parasites producing smaller microspores (3 to 6 μm) and complete their life cycles in a single host cell, generally with no alternate hosts. Identified microsporidian species in bivalve molluscs include *Steinhausia ovicola* and *S. mytilovum* that are parasites of ova in female bivalves and cause no significant harm. Several other unidentified microsporidia have been described in ova, connective tissues and the digestive gland but also causing no significant disease.

II. Host Species

Steinhausia has been described parasitizing wild and cultured bivalves in the ova of the European flat oyster (*S. ovicola*), oocytes of blue and gallo mussels (*S. mytilovum*) and cockles (*Steinhausia* sp.) in France, in *Mytilus* sp. (*S. mytilovum*) from Korea and Japan, the blue mussel (*S. mytilovum*) from the Atlantic coast and in the gallo mussel (*S. mytilovum*) on the Pacific coast of the U.S., Italy, Spain and Greece. Other unidentified microsporidia have been reported from: the ova of Australian blacklipped oysters; connective tissues surrounding the gut of New Zealand dredge oysters; connective tissues of the digestive gland in queen scallops in the United Kingdom; the digestive gland of cockles in France; and in the U.S. from ova of *Macoma* clams in Maryland and from ova of Pacific oysters in California. In Alaska, *Steinhausia*-like

sporonts have been observed in the ova of native littleneck clams and spores of unidentified microsporidia have occurred in the nervous tissue, mantle connective tissue and foot muscle of littleneck clams and basket cockles.

III. Clinical Signs

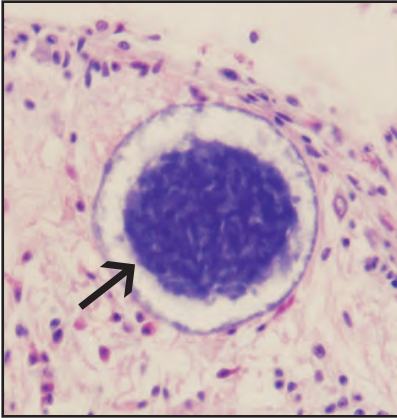
Parasitized bivalves appear healthy with no clinical signs of disease or mortality. The microsporidia in ova and various other tissues are incidental findings during routine histological examination.

IV. Transmission

Transmission is horizontal when spores released from ruptured host cells are ingested by a suitable host. In the intestine of the new host each spore releases a hollow polar tube attaching the spore to a mucosal epithelial cell through which the internal amoeboid sporoplasm passes into the host cell. The sporoplasm may replicate in the intestinal cell or may be injected into a host phagocyte where it travels to other target tissues. In addition to transmission via the alimentary tract, reports have hypothesized that *Steinhausia* sp. may also be vertically transmitted to progeny when lightly parasitized ova develop normally. Replication of *Steinhausia* sp. has also been reported in oocyte nuclei of some bivalve species. Once in the target host cell the parasite undergoes further replication and development involving merogony producing plasmodia and meronts followed by sporogony producing sporonts that contain sporoblasts that mature into spores. The entire process is complex and may have other intermediate stages depending on the species of microsporidia.

V. Diagnosis

Histological examination may detect the presence of microspores within various bivalve tissues or within sporocysts in the cytoplasm of maturing or well developed ova. Multiple immature sporonts (sporocysts) may be present with no visible spores. Genus and species identification by histology alone is generally not possible and would require closer morphological examination by transmission electron microscopy.



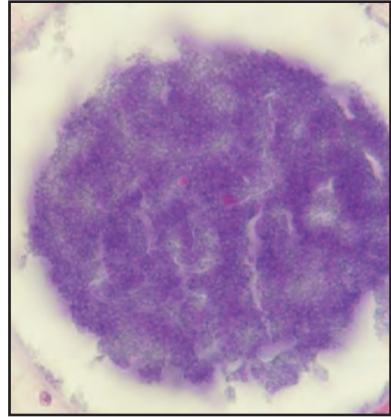
Histological section of microspores (arrow) of an unidentified microsporidian in the pallial nerve of basket cockle

VI. Prognosis for Host

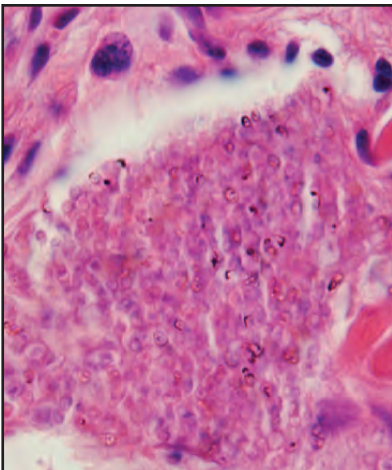
Microsporidian parasites do not appear to cause significant harm to their bivalve mollusc hosts.

VII. Human Health Significance

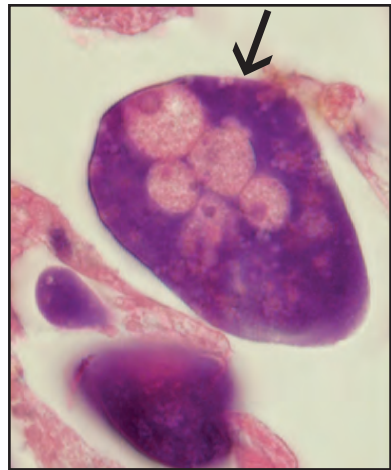
There are no zoonotic human health concerns regarding the presence of microsporidian parasites within the tissues of bivalve molluscs.



Higher magnification of microspores at left



Microspores of an unidentified microsporidian in the foot muscle of basket cockle



Sporonts of a *Steinhausia*-like microsporidian in an oocyte (arrow) of native littleneck clam